

Acute lamotrigine overdose: a systematic review of published adult and pediatric cases

Bader Alyahya, Marjorie Friesen, Bénédicte Nauche & Martin Laliberté

To cite this article: Bader Alyahya, Marjorie Friesen, Bénédicte Nauche & Martin Laliberté (2018) Acute lamotrigine overdose: a systematic review of published adult and pediatric cases, *Clinical Toxicology*, 56:2, 81-89, DOI: [10.1080/15563650.2017.1370096](https://doi.org/10.1080/15563650.2017.1370096)

To link to this article: <https://doi.org/10.1080/15563650.2017.1370096>



Published online: 01 Sep 2017.



Submit your article to this journal [↗](#)



Article views: 1407



View related articles [↗](#)

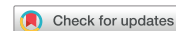

View Crossmark data [↗](#)



Citing articles: 9 View citing articles [↗](#)

REVIEW



Acute lamotrigine overdose: a systematic review of published adult and pediatric cases

Bader Alyahya^{a,b}, Marjorie Friesen^c, Bénédicte Nauche^d and Martin Laliberté^{e,f}

^aClinical Pharmacology and Toxicology Program, McGill University, Montreal, QC, Canada; ^bEmergency Department, King Saud University, Riyadh, Saudi Arabia; ^cPharmacy Department, McGill University Health Centre, Montreal, QC, Canada; ^dLibrary Department, McGill University Health Centre, Montreal, QC, Canada; ^eMcGill University Health Centre, Emergency Medicine, McGill University, Montreal, QC, Canada; ^fCentre anti-poison du Québec, Quebec City, QC, Canada

ABSTRACT

Context: Lamotrigine is a broad-spectrum anticonvulsant commonly used to treat seizure and bipolar mood disorders. Evidence from case series and retrospective studies indicate that lamotrigine overdose is usually benign. However, there are reported cases of cardiac arrest and mortality following lamotrigine overdose. We undertook a systematic review of the literature on lamotrigine overdoses to better understand the clinical severity, the relevance of serum concentrations, and therapeutic interventions for overdose.

Objectives: To characterize manifestations of acute lamotrigine overdose, determine if serum concentrations predict poisoning severity, and evaluate the effectiveness of overdose management interventions.

Methods: We performed a literature search across eight databases, including Medline, EMBASE, and the Cochrane Library, from database inception to April 2014. Major bibliographic databases were updated on 31 May 2017. Articles were eligible if they described acute or acute on chronic lamotrigine overdose. At least one serum lamotrigine concentration had to be reported for inclusion. Reports on chronic poisoning, studies describing adverse effects of therapeutic use, and animal studies were excluded.

Results: We retrieved 6238 records; 48 (51 cases) met the inclusion criteria. Cases primarily involved adults (70.6%). Potentially life-threatening symptoms of overdose included seizures (55%), Glasgow Coma Scale ≤ 8 (20%), hypotension (12%), and wide complex tachycardia (WCT) and cardiac arrest (6%). Among the 25 cases exposed to lamotrigine alone (13 adult; 12 pediatric), 2 adult fatalities occurred (4 g and 7.5 g ingested) and 8 pediatric cases experienced seizures (all children ≤ 3.5 -years-old, 75% without an underlying seizure disorder, ≥ 525 mg ingested). The lowest seizure-associated serum concentration was 3.8 mg/L and 25.6 mg/L for pediatric and adult patients, respectively, suggesting children may be more susceptible to CNS toxicity. Cardiovascular toxicities occurred primarily in adult patients (threshold >25 mg/L). Overdose interventions included benzodiazepines (53%), propofol or barbiturates (14%), NaHCO_3 (20%), lipid therapy (12%), and extracorporeal elimination (10%). NaHCO_3 yielded no response in four of nine cases with conduction delays; however, two of the four cases subsequently responded with lipid therapy.

Conclusions: Most cases reporting lamotrigine exposures observed mild or no toxicity; however, large exposures were associated with severe CNS depression, seizures, cardiac conduction delays, wide complex tachycardia, and death. In adults with a serum concentration >25 mg/L, severe toxicity may occur. In patients ≤ 3.5 years of age, ingestions of ≥ 525 mg may produce severe CNS depression and seizures.

ARTICLE HISTORY

Received 29 March 2017
Revised 15 August 2017
Accepted 17 August 2017
Published online 30 August 2017

KEYWORDS

Acute overdose; acute on chronic overdose; clinical manifestations; serum concentration; therapeutic interventions

Introduction

Lamotrigine is a phenyltriazine-class, broad-spectrum antiepileptic. It was first used clinically in Europe in 1990 [1]. Lamotrigine blocks voltage-gated sodium channels. This mechanism of action suppresses depolarization in regions with excessive electrical discharge (epileptic foci). It also decreases the release of excitatory neurotransmitters, such as glutamate and aspartate by blocking calcium channels [2]. Lamotrigine has excellent oral bioavailability (approximately 98%), and the peak serum concentration occurs within 3 h

after therapeutic doses. The volume of distribution is 1.1 L/kg, and at therapeutic concentrations, only 55% of lamotrigine is bound to plasma proteins. When lamotrigine is conjugated with glucuronic acid, it forms inactive metabolites that are excreted in the urine. The plasma half-life in healthy volunteers not taking other medications is approximately 33 h, with considerable inter-individual variation (range 22–36 h) [1]. The therapeutic concentration range for patients with epilepsy varies between studies; however, a trough range of 1–4 mg/L is recommended [3,4]. In a small

prospective study ($N=50$), 32 patients (64%) were seizure free and had no adverse effects at serum concentrations of 1.4–18.7 mg/L. Only three patients had concentrations >10 mg/L [5]. A larger retrospective study ($N=811$) found that adverse effects were rare at concentrations <10 mg/L and recommended a therapeutic concentration range of 1.5–10 mg/L [6].

Lamotrigine has approved uses for the treatment of various seizure disorders and acute treatment and maintenance therapy of bipolar depression [7,8]. Off-label uses include treatment of various neuropathic pain conditions and migraine prophylaxis [9–11]. The use of lamotrigine for the treatment of psychiatric disorders has increased dramatically over the years. For example, a Norwegian study of antiepileptic drug prescriptions found a rapid increase in lamotrigine use for psychiatric indications from roughly less than 0.02 to 1 defined daily doses/1000 inhabitants per day from 2004 to 2007 [12].

Given the expanding number of indications for lamotrigine, the likelihood of intentional and unintentional exposures could also increase. Several case reports and two retrospective case series have reported on lamotrigine overdose previously [13,14]. Evidence from these early publications suggested that lamotrigine overdose is usually benign. However, seizures, cardiac arrest, and mortality following lamotrigine overdose have also been reported. Given this conflicting information, we performed a systematic review of the lamotrigine overdose literature. The aim of this study was to characterize manifestations of acute lamotrigine overdose, determine if serum concentrations are predictive of poisoning severity, and describe the effectiveness of therapeutic interventions used to manage an overdose.

Materials and methods

This systematic review investigated the literature reporting on cases of acute and acute on chronic lamotrigine overdose in human. The study protocol was constructed in advance and registered with PROSPERO International prospective register of systematic reviews (<http://www.crd.york.ac.uk/PROSPERO/index.asp>; registration number: CRD42014014059).

The following definitions were used for this review. We defined “acute exposure” as an intentional or unintentional acute ingestion of lamotrigine occurring within a 24-h period in a patient who had not been exposed to lamotrigine previously. We defined “acute on chronic exposure” as an intentional or unintentional acute ingestion of lamotrigine occurring within a 24-h period in a patient who had been exposed to lamotrigine previously (e.g., prescribed for a seizure disorder). We defined “chronic exposure” as exposure to lamotrigine due to therapeutic use or ingestion of supra-therapeutic doses for longer than 24 h. We defined an “adult” as a person 18 years of age or older and pediatric as a person younger than 18 years of age. We defined a serum lamotrigine concentration of 10 mg/L or higher as a supra-therapeutic concentration [6]. We defined “peak concentration” as the highest concentration reported in a given case which may not represent the actual peak concentration.

Eligibility criteria

We included all cases of acute and acute on chronic lamotrigine exposure in both adult and pediatric patients that reported at least one serum lamotrigine concentration to confirm exposure. We excluded cases of chronic exposure and reports of adverse effects due to therapeutic use. Articles not written in French or English were also excluded. While we defined 10 mg/L as the supra-therapeutic serum concentration threshold, we did not exclude cases based on serum concentrations as it was not possible to determine exactly when the blood samples were drawn (e.g., the serum concentration was at a therapeutic range because it was collected late in the course of the overdose).

When a report did not clearly meet the inclusion or exclusion criteria, data extractors [M. F. and B. A.] took the following actions to reach a consensus. We attempted to contact the authors for additional information. For cases where a consensus between the data extractors could not be reached, the final decision was left to the reviewer [M. L.].

Outcome measures

The primary outcome measure was the clinical manifestations of acute or acute on chronic lamotrigine overdose. Secondary outcomes included the relationship between the highest reported serum lamotrigine concentration for each case and poisoning severity as well as therapeutic overdose interventions and their effectiveness.

Search strategy

With librarian assistance, a comprehensive search strategy was developed. We searched the following databases for relevant articles: Medline via OvidSP, EMBASE via OvidSP, the Cochrane Library via Wiley, PsycINFO via OvidSP, Biosis Previews via OvidSP, CINAHL via EBSCOhost, Scopus, and Web of Science. The period included in the search was from the respective inception dates of the databases through 24 April 2014. To update the results, searches were run again 31 May 2017 in Medline, Embase, the Cochrane Library, PsycINFO, and Biosis. In addition, we manually checked abstracts from two conferences: the North American Congress of Clinical Toxicology and the International Congress of the European Association of Poison Centers and Clinical Toxicologists from 1994 to 31 May 2017. The references from selected articles were reviewed manually for relevant papers. Two reviewers who were blinded to authors and journal names independently selected studies based on eligibility criteria. Any disagreements were discussed between reviewers until a consensus was reached. Then, the reviewers independently extracted relevant data using the same pre-designed data extraction form. Extracted data included the year of publication, journal and author names, indication for lamotrigine, dose ingested, time of ingestion, serum drug concentration, presence of co-ingestants, vital signs, clinical manifestations, treatment provided, intensive care admission, duration of hospitalization, and complications.

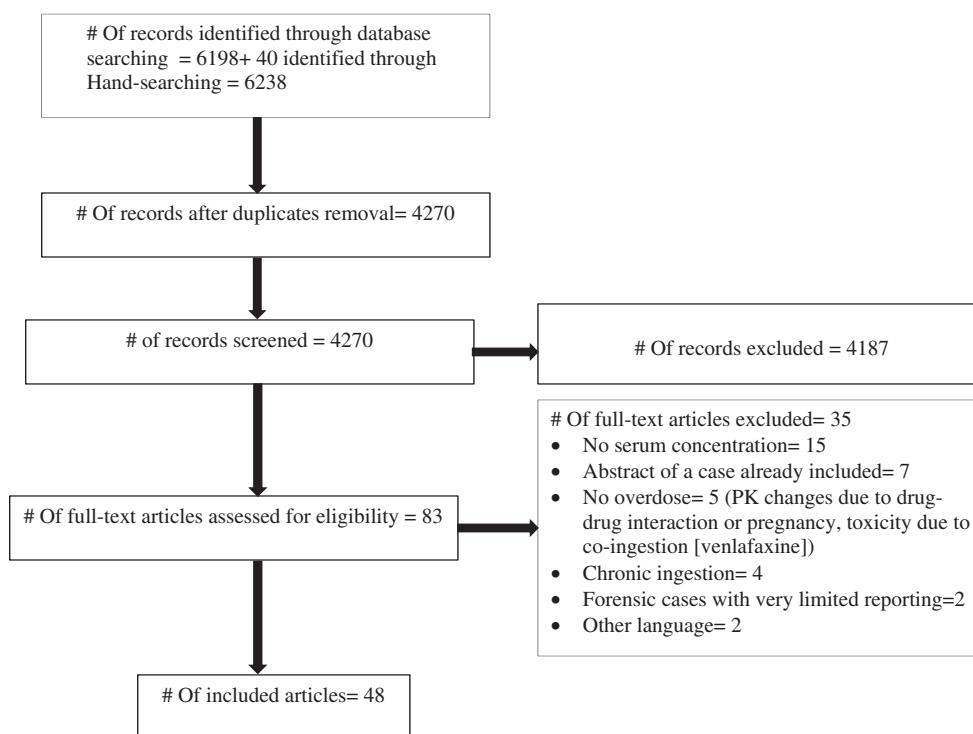


Figure 1. Flow diagram of the different phases of the literature review.

Results

The literature search identified 6198 records; 5280 in the original search and an additional 918 in the final update conducted on 31 May 2017. Hand-searching conference abstracts identified 21 records in the original search and an additional 19 with the final update. Duplicate records were removed leaving in total 4270 records that were screened and of those, 48 reports (51 cases) met our inclusion criteria. Of those, 17 records (18 cases) were conference abstracts [15–31], and 31 records (33 cases) were published case reports [32–61]. Figure 1 shows a flow diagram of the literature search at different phases during the review process.

We identified 51 cases of acute lamotrigine overdose with a documented serum concentration. Among the cases, 28 (55%) involved female patients and 21 (41%) involved male patients. The gender was not specified in two cases. The patients' ages ranged from 12 days to 71 years. Most patients had been prescribed lamotrigine for the treatment of psychiatric ($N=16$; 31%) or seizure disorders ($N=15$; 29%). Eleven patients had not been prescribed lamotrigine and ingested it either accidentally, intentionally as part of a suicide attempt, or in one case, an act of child abuse. The circumstances for lamotrigine exposures were not provided in nine cases.

Clinical features of lamotrigine overdose

Clinical manifestations of lamotrigine overdose are summarized in Table 1 and most commonly involved the central nervous system (CNS) and cardiovascular system.

Table 1. Clinical manifestations.

Clinical manifestation	N (%)
Altered consciousness/GCS ≤ 8	42 (82%)/10 (20%)
Seizure/Status epilepticus	28 (55%)/10(20%)
Agitation	22 (43%)
Tachycardia	17 (33%)
Ataxia	16 (31%)
QRS >100	11 (21%)
Nystagmus	10 (20%)
Hyperreflexia	9 (18%)
Vomiting	7 (14%)
Hypotension	6 (12%)
Tremor	6 (12%)
Rhabdomyolysis/acute kidney injury	3 (6%)/2 (4%)
Wide complex tachycardia	3 (6%)
Cardiac arrest	3 (6%)

GCS: Glasgow coma scale.

CNS manifestations

The most commonly reported clinical manifestation of lamotrigine overdose was altered sensorium ranging from mild drowsiness and lethargy to coma (82%). In 28 cases (55%), patients experienced seizures, and 10 patients developed status epilepticus. For six pediatric and six adult cases, patients had no prior history of seizure disorder and had no co-ingestion prior to experiencing seizures (Tables 2 and 3). Ten patients (20%) presented with severe obtundation, defined as a Glasgow coma scale ≤ 8 .

Cardiovascular manifestations

The most frequently reported cardiovascular manifestation was tachycardia (33%). In 11 cases (21%), QRS widening greater than 100 ms was detected

Table 2. Pediatrics patients who developed seizures following lamotrigine overdose.

Author	Year	Indication for LTG	Seizure: S/M/status	Age	Dose g (mg/kg)	Serum concentration mg/L	HPI	Co-ingestion
Willis et al. [56]	2007	Factitious	M	12 d	N/A	35	N/A	None
Lapoint et al. [24]	2010	Father's medication	M	13 mo	0.8	31	3	None
Abesamis et al. [15]	2010	Mother's medication	M	20 mo	1.5	30.5	11	None
Grosso et al. [58]	2016	Father's medication	Status	3 y	1.6	28.4	N/A	None
Sirianni et al. [51]	2008	Bipolar	S	17 y	4 (72.7)	26	6.5	Bupropion
Moore et al. [14]	2013	Seizure	S	2 y	0.5 (38.9)	26	N/A	None
Bartecka-Mino et al. [29]	2017	N/A	S	2 y	(6.5)	25.3	N/A	None
Thundiylil et al. [52]	2007	Sister's medication	M	19 mo	N/A	20.3	1	None
Briassoulis et al. [34]	1998	Mother's medication	Status	2 y	0.8 (61.6)	3.8	2	None

LTG: lamotrigine, S: single seizure episode, M: multiple seizure episodes, Status: status epilepticus, y:year, mo: month, d:day N/A: not available, HPI: hours post-ingestion when concentration was measured.

Table 3. Adult patients who developed seizures following lamotrigine overdose.

Author	Year	Indication for LTG	Seizure: S/M/status	Dose g (mg/kg)	Serum concentration mg/L	HPI	Co-ingestion
Moore et al. [14]	2013	Bipolar	S	N/A	90	16.7	Fludrocortisone
Chavez et al. [37]	2015	Bipolar	Status	13.5	78	2	None
Nogar et al. [45]	2011	Depression	Status	7.5	74.7	1.5	None
Hajiali and Nassiri-Asl [59]	2015	Bipolar	S	40	73	Day 2	None
Williams and Watkins [26]	2011	N/A	Status	N/A	64.2	N/A	Fluoxetine, Ethanol
Lu et al. [44]	2012	Bipolar	S	N/A	61.2	4	Clonazepam
Deslandes et al. [60]	2015	Seizure	Status	8	53.6	1	Lacosamide
Kornhall and Nielsen [42]	2014	Bipolar	S	N/A	49	N/A	None
Jobst and Williamson [23]	2005	Seizure	Status	4.1	47.4	N/A	None
Dinnerstein et al. [39]	2007	Seizure(P)	Status	4.1	47.4	Day 2	None
Braga and Chidley [33]	2007	Seizure	M	32	45	Day1	Pregabalin
Dagtekin et al. [38]	2011	Depression	S	20 (333)	42.4	N/A	Venlafaxine/diazepam
French et al [40]	2011	Bipolar	M	4	35.7	19	None
Waring [54]	2009	Alcohol withdrawal seizures	S	N/A	30	1.3	None
Algahtani et al. [32]	2014	Bipolar	Status	6	25.6	N/A	None
Schwartz and Geller [49]	2007	Bipolar	M	N/A	25.2	N/A	Ethanol
Herold [41]	2006	Seizure	M	N/A	14.8	N/A	Felbamate
Sethi et al. [50]	2013	Depression	Status	N/A	12.5	12-h post-admission	Bupropion
Cheema and Leikin [27]	2014	Depression	S	0.6	3.8	12	Venlafaxine and Melatonin

LTG: lamotrigine, S: single seizure episode, M: multiple seizure episodes, N/A: not available, HPI: hours post-ingestion when concentration was measured. P: partial.

[14,16,26,35–37,40,41,45,51,53]. Wide complex tachycardia (included only if the term WCT was used by the author) and cardiac arrest were reported in three cases (6%). The only cardiac toxicity reported in the pediatric population was sinus tachycardia [52].

Lamotrigine-only overdose cases

Details from cases of lamotrigine-only overdoses are provided in Table 4. Twenty-five cases of lamotrigine-only overdoses met our inclusion criteria. Two cases resulted in death. The first was described by French et al. [40] a 19-year-old male with a history of bipolar disorder and no other medical illness who ingested 4g of lamotrigine. Despite early presentation to an emergency department (15 min after the witnessed ingestion) and rapid decontamination, the patient had multiple seizure episodes then developed aspiration pneumonia, complete heart block, and encephalopathy. Care was withdrawn 10-days post-admission. Screening for drugs of abuse was negative, and the family denied access to other medications. The second case described by Nogar et al. [45] was a 48-year-old woman with no history of seizure disorder who ingested 7.5g of lamotrigine. She developed refractory seizures then pulseless WCT

resulting in anoxic brain injury. Care was withdrawn 4-days post-admission.

Among 13 adult cases of lamotrigine-only overdose, 6 developed seizures in the absence of a seizure disorder and 3 of them had status epilepticus (Table 4). Cardiac toxicity was reported in five cases, including one case of WCT and one complete heart block. Among 12 pediatric cases of lamotrigine-only overdose, 8 experienced seizures. Six of those patients had no history of seizure disorders (Table 4).

Serum lamotrigine concentration and poisoning severity

Frequently, clinicians do not know the time between ingestion and the measurement of serum lamotrigine concentrations. In our included cases, most reported only a single concentration, and when multiple concentrations were reported, we selected the highest concentration. In adults who had no history of seizure disorder and had not co-ingested another drug, Algahtani et al. [32] reported a single lamotrigine concentration of 25.6 mg/L, measured at an unknown time post-ingestion. This represents the lowest concentration of lamotrigine in the adult cases with seizures. Among nine children who developed seizures, there were two cases (with no other co-ingestants) in which serum lamotrigine concentrations were lower than those reported

Table 4. Cases of lamotrigine-only overdose.

Author	Year	Age	Indication for LTG	Seizure: S/M/status	Dose g (mg/kg)	Serum concentration mg/L	HPI	ECG	Outcome
Chavez et al. [37]	2015	36 y	Bipolar	Status	13.5	78	2	QRS = 128	Survived to rehab
Nogar et al. [45]	2011	48 y	Depression	Status	7.5	74.7	1.5	WCT	Death
Hajiali and Nassiri-Asl [59]	2015	26 y	Bipolar	S	40	73	Day 2	Sinus tachycardia	Survived
Miller and Levsky [25]	2008	23 y	Bipolar	None	N/A	63.9	4-h post-admission	N/A	Survived
Hernandez et al. [22]	2010	40 y	Seizure	None	6	49.5	NA	Un-remarkable	Survived
Kornhall and Nielsen [42]	2014	N/A	Bipolar	S	N/A	49	N/A	N/A	Survived
Dinnerstein et al. [39]	2007	42 y	Seizure (P)	Status	4.1	47.4	2 days	N/A	Survived
French et al. [40]	2011	19 y	Bipolar	M	4	35.7	19	Wide QRS then CHB	Death
Willis et al. [56]	2007	12 d	Child abuse	M	N/A	35	N/A	Normal	Survived
Lapoint et al. [24]	2010	13 mo	Accidental	M	0.8	31	3	Normal	Survived
Abesamis et al. [15]	2010	20 mo	Accidental	M	1.5	30.5	11-h post-admission	Normal	Survived
Chiew et al. [17]	2013	18 mo	Accidental	None	N/A	30.3	N/A	N/A	Survived
Waring [54]	2009	42 y	Alcohol withdrawal Seizure	S	N/A	30	1.3	Normal	Survived
Castanares-Zapatero et al. [36]	2012	50 y	Bipolar	None	3.5	29.7	6	QRS = 160	Survived
Grosso et al. [58]	2016	3 y	Accidental	Status	1.6	28.4	N/A	Sinus tachycardia, RBBB	Survived
Moore et al. [14]	2013	2 y	Seizure	S	0.5 (38.9)	26	3	N/A	Survived
Algahtani et al. [32]	2014	46 y	Bipolar	Status	6	25.6	N/A	N/A	Survived
Zidd and Hack [57]	2004	3 y	Seizure	None	1.2	25.3	1.5	NA	Survived
Bartecka-Mino et al. [29]	2017	2 y	N/A	S	(6.5)	25.3	N/A	N/A	Survived
Thundiyil et al. [52]	2007	19 mo	Accidental	M	N/A	20.3	1	NA	Survived
Dlugopolski et al. [18]	2007	4 y	Accidental	None	0.6-1	18.8	25	NA	Survived
Moore et al. [14]	2013	1 y	Accidental	None	N/A	18	8	N/A	Survived
Buckley et al. [35]	1993	26 y	Temporal lobe epilepsy	None	1.4	17.4	3	QRS = 112	Survived
Veerapandiyani et al. [61]	2011	25 y	Seizure	None	1.6 (23.5)	16.5	N/A	NA	Survived
Briassoulis et al. [34]	1998	2 y	Accidental	Status	0.8 (61.6)	3.8	2	No dysrhythmia	Survived

LTG: lamotrigine, S: single seizure episode, M: multiple seizure episodes, N/A: not available, HPI: hours post-ingestion when concentration was measured, P: partial, WCT: wide complex tachycardia, CHB: complete heart block, y: year, mo: month, d: day.

in adults. Briassoulis et al. [34] described a 2-year-old child who accidentally ingested his mother's medication and experienced a tonic-clonic seizure lasting 15 min prior to arrival in hospital. The lamotrigine concentration collected 2-h post-ingestion was 3.8 mg/L and represents the lowest concentration associated with seizures in all the included cases and a concentration that is within the therapeutic range for adults (1.5–10 mg/L) [6]. Thundiyil et al. [52] reported a 19-month old child who had no history of prior seizure disorders that experienced seizures with a serum lamotrigine concentration of 20.3 mg/L measured at 1 h post-ingestion.

Therapeutic interventions and their effectiveness

Gastrointestinal decontamination

Fifteen cases (29%) reported activated charcoal use [19,20,25,32,34–38,40,47,49,52,57,59]. Nine cases (18%) reported gastric lavage use [19,34,35,38,40,44,47,57,59]. One patient (2%) received whole bowel irrigation (WBI) [19]. Based on the available data, we could not estimate the impact of gastrointestinal decontamination on patient outcome.

Seizure treatment

Twenty patients received benzodiazepines to treat seizures. Termination of seizure occurred in 12 cases

[23,24,33,34,39–41,49,54,58,59,60], while 5 patients required additional treatment [26,32,37,45,56]. Three case reports did not provide the response to treatment [15,38,50]. Four patients received phenytoin or fosphenytoin [32,33,45,56]. Two of these patients had prior history of seizure disorder [33,45]. Six patients received barbiturates and or propofol to control seizures [26,32,37,45,59,60].

Treatment of conduction delays

Ten cases (20%) reported sodium bicarbonate use, which produced varying responses. The QRS complex did not correct in four cases [26,36,37,45]. Sirianni et al. [51] reported a nonfatal case of bupropion and lamotrigine overdose, spontaneous circulation returned 2 min after sodium bicarbonate administration, but the patient re-arrested and subsequent sodium bicarbonate was ineffective but the return of spontaneous circulation occurred one minute after intralipid emulsion administration. Herold [41] described a patient who ingested lamotrigine and felbamate; the electrocardiogram showed QRS complex narrowing from 108 ms to 98 ms following the administration of one dose of sodium bicarbonate. In one case by Bouchard et al. [16] ST segment elevation in precordial leads decreased, but there was no observable effect on the QRS interval with sodium bicarbonate. Response was not reported in two cases [40,53]. Hajiali and

Nassiri-Asl [59] used sodium bicarbonate prophylactically in one case that never developed conduction delay.

Intravenous lipid emulsion was used in six cases including the case described above by Sirianni et al. [51]. In two cases of lamotrigine-only overdose, ILE rapidly narrowed the QRS complex and resolved the conduction delay after sodium bicarbonate therapy failed [36,37]. Moore et al. [14] reported improvement of agitation in a patient who overdosed on lamotrigine and fludrocortisone, which could have been secondary to ILE administration. Dagtekin et al. [38] reported resolution of rigidity, hyperreflexia, and restoration of spontaneous ventilation in a patient who overdosed on diazepam, venlafaxine, and lamotrigine following the administration of ILE. Nogar et al. [45] described a patient with pulseless WCT following ingestion of 7.5 g lamotrigine who had no response to ILE treatment.

Extracorporeal elimination

Extracorporeal treatment was used in five cases, intermittent hemodialysis (IHD) in four cases, and continuous veno-venous hemofiltration in one case. Williams and Watkins [26] reported resolution of seizures and WCT 45 min after the initiation of hemodialysis. IHD was performed for 3.5 h. Serum lamotrigine concentrations at 20 min, 57 min, and 4 h after IHD initiation were 64.2, 57, and 39.2 mg/L, respectively. In one of the fatal lamotrigine-only overdoses described by French et al. [40], lamotrigine was still detectable in serum after five sessions of IHD performed over a period of 8 days. The first four sessions were 3 h each, and the fifth was 2.5 h long. In this case, the half-life of lamotrigine with once-daily IHD varied between 16.6 and 60.6 h. The authors hypothesized that the prolonged half-life and the non-linear reduction of lamotrigine concentration could have been due to ongoing absorption or bezoar formation. In the case reported by Dagtekin et al. [38], a single 8-h IHD session did not improve rigidity and hyperreflexia. The serum concentration in that case was measured only once prior to IHD, which precludes calculating lamotrigine half-life. Chavez et al. [37] described a patient that showed improvement in acid-base status following continuous veno-venous hemofiltration with a sodium bicarbonate infusion, but no effect was observed on cardiovascular toxicity. Hemofiltration was continued for 1 week. The authors did not report serum concentrations or half-life calculations. In the case reported by Lu et al. [44] of mixed lamotrigine and clonazepam overdose, there was paucity of reported information; therefore, the effects of IHD and hemoperfusion could not be assessed.

Discussion

Cardiovascular and neurological toxicity following lamotrigine overdose is likely secondary to its ability to block voltage-gated sodium channels [14]. Blocking fast sodium channels in the heart prolongs the QRS complex and can lead to ventricular tachycardia and cardiovascular collapse. Lofton and Klein-Schwartz [13] conducted a large ($N=493$) retrospective poison center study of lamotrigine-only exposures. Most

patients in that study experienced little or no effects. Seizures, coma, respiratory depression, and conduction delays occurred in less than 1.2% of patients. There was no reported mortality in that study. Unfortunately, the authors did not report serum concentrations. In our review, lamotrigine overdose resulted in seizures in 55% of cases, severe depression of mental status (Glasgow coma scale ≤ 8) in 20%, WCT and cardiac arrest in 6%, and death in 6%. This difference in the complication rates may be explained partly by selection and confirmation bias in the former and publication bias in the latter. It is likely that most lamotrigine exposures result in mild or no toxicity. However, ingestion of large quantities can be associated with severe CNS depression, seizures, cardiac conduction delays, WCT, and death.

The therapeutic range and usefulness of monitoring serum lamotrigine concentrations in patients with epilepsy are controversial. Earlier studies found no correlation between the serum concentration and clinical efficacy or toxicity [5,62]. However, Hirsch et al. [6] showed a strong correlation between serum lamotrigine concentration and clinical toxicity. In their study, the percentage of patients experiencing signs and symptoms of toxicity increased with serum concentration, and 59% of patients with a concentration >20 mg/L showed some evidence of toxicity. In our review, the lowest serum concentration associated with seizure or cardiac toxicity was 25.6 mg/L in adult patients who had no history of seizures and overdosed on lamotrigine alone. The majority of the pediatric patients in our review were ≤ 3.5 years of age, which limits the generalizability of our findings; ingestions as low as 525 mg of lamotrigine caused significant toxicity in one patient in this age group. In addition seizures were reported at a lower serum concentrations (3.8 mg/L and 20.3 mg/L) in two pediatric cases compared to those seen in adults. Bartecka-Mino et al. [29] in a conference abstract of a retrospective poison information study that included 43 pediatric cases recommended careful assessment of pediatric lamotrigine overdose as they seem more susceptible to its toxic effect. It appears that children may be more susceptible to seizures with lamotrigine ingestions. However, given that the timing of the concentration with respect to the time of ingestion was often not reported (Tables 2 and 3) and higher serum concentrations in the same age group resulted in significant but less severe toxicity [17]; more evidence is needed to support or refute this observation.

Inter-patient variability in serum lamotrigine concentrations (i.e., the same dose results in different serum concentrations in different patients) is well documented [63,64]. This may partly explain why smaller ingestions resulted in more severe toxicity in some patients.

Regarding therapeutic management of lamotrigine overdose, activated charcoal was used in 29% of cases in our review. Estimating the impact of activated charcoal on patient outcome is difficult because it was often administered late after ingestion. However, activated charcoal has been shown in healthy volunteers studies to reduce lamotrigine absorption and enhances its elimination [65,66]. Therefore, we recommend using activated charcoal in the absence of contraindications. Lamotrigine causes alterations in consciousness level and seizures; therefore, protecting the

airway prior to GI decontamination is essential. WBI was used in one case in our review. WBI could be useful when the patient ingests a sustained-release formulation; however, polyethylene glycol could decrease lamotrigine binding to activated charcoal. Lamotrigine circulates enterohepatically, and the use of multiple-dose activated charcoal may enhance its elimination [66].

Lamotrigine-induced seizures should be treated like other toxicological seizures. Benzodiazepines are the first-line treatment, and propofol and barbiturates should be used for refractory seizures. Phenytoin should probably be avoided since, like lamotrigine, it inhibits the electrical discharge in the epileptic focus by blocking sodium channels. There are more sodium channels in the inactivated state located at the epileptic focus due to the high frequency of depolarization. Phenytoin can bind to the inactivated channels and inhibit their reactivation [67]. In the case of overdose, the balance between excitatory and inhibitory neurotransmitters is lost due to excessive release of the former and blockade or deficiency of the latter, but there is no specific focus with excessive electrical discharge [68].

While QRS widening was resistant to sodium bicarbonate therapy in several cases in our review, two cases reported resolution of conduction delay following its administration [41,51]. Whether lamotrigine-induced cardiac conduction delays are truly resistant to sodium bicarbonate therapy is unclear. Failure to respond to sodium bicarbonate therapy in the reported cases may have been influenced by delays in the initiation of treatment or inadequate dosing. The place in therapy of this intervention cannot be established based on the reported cases included in our review. Definitive conclusions concerning the role of ILE in lamotrigine poisoning are not possible from the available data. ILE could be considered when sodium bicarbonate is ineffective in hemodynamically unstable patients and in cases of cardiac arrest.

The pharmacokinetic profile of lamotrigine indicates that it may be amenable to extracorporeal elimination; however, the number of cases in our review using extracorporeal elimination was small, and the serum concentrations were rarely measured more than once after extracorporeal elimination was initiated. Therefore, we could not assess lamotrigine clearance using these treatment modalities.

Our review has several limitations; it is based entirely on case reports and case series, which diminish the strength of the evidence. We did not find any prospective studies addressing lamotrigine overdose in the literature or conference abstracts. It is possible that by restricting our inclusion criteria to acute and acute-on-chronic lamotrigine overdose exposures that included a serum concentration biased our results toward more severe cases, as obtaining concentrations may be more likely performed in severe poisonings. Publication bias and the lack of a standardized methodological approach for case reports is another limitation. In addition, most of the pediatric cases included in this review were ≤ 3.5 years of age, which hinders extrapolation of these results to older pediatric patients. Lastly, it is important to realize that some of our observations are based on small number of cases and larger trials are needed to confirm such observations.

Conclusions

Most cases reporting lamotrigine exposures observed mild or no toxicity. However, large exposures were associated with severe CNS depression, seizures, cardiac conduction delays, wide complex tachycardia, and death. In adults with a serum concentration >25 mg/L, severe toxicity may occur. In patients ≤ 3.5 years of age, ingestions of ≥ 525 mg may produce severe CNS depression and seizures.

Disclosure statement

There are no conflicts of interest.

References

- [1] Biton V. Pharmacokinetics, toxicology and safety of lamotrigine in epilepsy. *Expert Opin Drug Metab Toxicol.* 2006;2:1009–1018.
- [2] Kwan P, Sills GJ, Brodie MJ. The mechanisms of action of commonly used antiepileptic drugs. *Pharmacol Ther.* 2001;90:21–34.
- [3] George S, Wood AJ, Braithwaite RA. Routine therapeutic monitoring of lamotrigine in epileptic patients using a simple and rapid high performance liquid chromatographic technique. *Ann Clin Biochem.* 1995;32:584–588.
- [4] Rambeck B, Wolf P. Lamotrigine clinical pharmacokinetics. *Clin Pharmacokinet.* 1993;25:433–443.
- [5] Kilpatrick ES, Forrest G, Brodie MJ. Concentration–effect and concentration–toxicity relations with lamotrigine: a prospective study. *Epilepsia.* 1996;37:534–538.
- [6] Hirsch LJ, Weintraub D, Du Y, et al. Correlating lamotrigine serum concentrations with tolerability in patients with epilepsy [Research Support, Non-U.S. Gov't Review]. *Neurology.* 2004;63:1022–1026.
- [7] Yatham LN, Kennedy SH, Parikh SV, et al. Canadian Network for Mood and Anxiety Treatments (CANMAT) and International Society for Bipolar Disorders (ISBD) collaborative update of CANMAT guidelines for the management of patients with bipolar disorder: update 2013. *Bipolar Disord.* 2013;15:1–44.
- [8] Walpoth-Niederwanger M, Kemmler G, Grunze H, et al. Treatment patterns in inpatients with bipolar disorder at a psychiatric university hospital over a 9-year period: focus on mood stabilizers. *Int Clin Psychopharmacol.* 2012;27:256–266.
- [9] Jensen TS. Anticonvulsants in neuropathic pain: rationale and clinical evidence. *Eur J Pain.* 2002;6:61–68.
- [10] Backonja M. Neuromodulating drugs for the symptomatic treatment of neuropathic pain. *Curr Pain Headache Rep.* 2004;8:212–216.
- [11] Jackson JL, Cogbill E, Santana-Davila R, et al. A comparative effectiveness meta-analysis of drugs for the prophylaxis of migraine headache. *PLoS One.* 2015;10:e0130733.
- [12] Johannessen Landmark C, Larsson PG, Rytter E, et al. Antiepileptic drugs in epilepsy and other disorders—a population-based study of prescriptions. *Epilepsy Res.* 2009;87:31–39.
- [13] Lofton AL, Klein-Schwartz W. Evaluation of lamotrigine toxicity reported to poison centers. *Ann Pharmacother.* 2004;38:1811–1815.
- [14] Moore PW, Donovan JW, Burkhart KK, et al. A case series of patients with lamotrigine toxicity at one center from 2003 to 2012. *Clin Toxicol.* 2013;51:545–549.
- [15] Abesamis MG, Pizon A, Walsh S, et al. Accidental lamotrigine overdose in a 20-month old [Conference Abstract]. *Clin Toxicol.* 2010;48:653.
- [16] Bouchard N, Halcomb SE, Hoffman RS, et al. Lamotrigine and citalopram overdose: Unmasking a Brugada ECG pattern [Meeting Abstract]. *Clin Toxicol.* 2006;44:656–656.

- [17] Chiew AL, Cush K, Chan BSH. Prolonged delirium and abnormal movements in paediatric lamotrigine ingestion [Conference Abstract]. *Clin Toxicol.* 2013;51:319.
- [18] Dlugopolski PR, Katz KD, Krenzelok EP. Prolonged CNS toxicity in a child with lamotrigine poisoning [Meeting Abstract]. *Clin Toxicol.* 2007;45:615–616.
- [19] Eleftheriou G, Butera R, Faraoni L, et al. Ischemic colitis following duloxetine and lamotrigine poisoning: Is there a relationship? [Conference Abstract]. *Clin Toxicol.* 2010;48:282.
- [20] Eleftheriou G, Butera R, Zavaritt A, et al. Dystonic effects and false increase in lactate levels after lamotrigine poisoning [Conference Abstract]. *Clin Toxicol.* 2009;47:457–458.
- [21] Harchelroad F, Lang D, Valeriano J. Lamotrigine overdose [Meeting]. *Vet Hum Toxicol.* 1994;36:372.
- [22] Hernandez SH, Habib S, Howland MA, et al. Severe prolonged encephalopathy from an intentional lamotrigine overdose with significantly elevated and prolonged serum concentrations [Conference Abstract]. *Clin Toxicol.* 2010;48:645.
- [23] Jobst BC, Williamson PD. Status epilepticus as a result of acute lamotrigine intoxication [Meeting Abstract]. *Epilepsia.* 2005;46:279–279.
- [24] Lapoint J, Sullivan R, Rey L, et al. Massive, unintentional pediatric lamotrigine overdose resulting in seizures [Conference Abstract]. *Clin Toxicol.* 2010;48:607.
- [25] Miller MA, Levsky ME. Choreiform dyskinesia following isolated lamotrigine overdose [Case Reports Letter]. *J Child Neurol.* 2008;23:243.
- [26] Williams SR, Watkins B. Lamotrigine poisoning with severe neurotoxicity and cardiac dysrhythmias, treated with hemodialysis [Meeting Abstract]. *Clin Toxicol.* 2011;49:618–618.
- [27] Cheema N, Leikin JB. Delayed seizure due to venlafaxine ER and lamotrigine overdose [Conference Abstract]. *Clin Toxicol.* 2014;52:812–813.
- [28] Trella J, Lombardo M, Boroughf W, et al. Lamotrigine causes false positive field test for methylenedioxypropylvalerone [Abstract]. *Clin Toxicol.* 2016;54:659–881.
- [29] Bartecka-Mino K, Schiel H, Arif T. Lamotrigine enquiries to the Austrian Poisons Information Centre: a retrospective 14-year study [Conference Abstract]. *Clin Toxicol.* 2017;55:423.
- [30] Kristen Gruenthera TP, Joseph Y, Anthony P. Lamotrigine toxidrome of rapidly alternating somnolence and agitated delirium [Conference Abstract]. *Clin Toxicol.* 2016;54:730.
- [31] Vukovic-Ercegovic G, Perkovic-Vukcevic N, Potrebic O, et al. Acute lamotrigine overdoses treated at the Department of Emergency and Clinical Toxicology during a 3-year period clinical overview [Conference Abstract]. *Clin Toxicol.* 2017;55:421.
- [32] Algahtani HA, Aldarmahi AA, Al-Rabia MW, et al. Generalized myoclonus and spasticity induced by lamotrigine toxicity: a case report and literature review. *Clin Neuropharmacol.* 2014;37:52–54.
- [33] Braga AJ, Chidley K. Self-poisoning with lamotrigine and pregabalin [Case Reports]. *Anaesthesia.* 2007;62:524–527.
- [34] Briassoulis G, Kalabalikis P, Tamiolaki M, et al. Lamotrigine childhood overdose [Case Reports]. *Pediatr Neurol.* 1998;19:239–242.
- [35] Buckley NA, Whyte IM, Dawson AH. Self-poisoning with lamotrigine [Case Reports Letter]. *Lancet.* 1993;342:1552–1553.
- [36] Castanares-Zapatero D, Wittebole X, Huberlant V, et al. Lipid emulsion as rescue therapy in lamotrigine overdose [Case Reports]. *J Emerg Med.* 2012;42:48–51.
- [37] Chavez P, Casso Dominguez A, Herzog E. Evolving electrocardiographic changes in lamotrigine overdose: a case report and literature review. *Cardiovasc Toxicol.* 2015;15:394–398.
- [38] Dagtekin O, Marcus H, Muller C, et al. Lipid therapy for serotonin syndrome after intoxication with venlafaxine, lamotrigine and diazepam [Case Reports]. *Minerva Anesthesiol.* 2011;77:93–95.
- [39] Dinnerstein E, Jobst BC, Williamson PD. Lamotrigine intoxication provoking status epilepticus in an adult with localization-related epilepsy [Case Reports]. *Arch Neurol.* 2007;64:1344–1346.
- [40] French LK, McKeown NJ, Hendrickson RG. Complete heart block and death following lamotrigine overdose [Case Reports]. *Clin Toxicol.* 2011;49:330–333.
- [41] Herold TJ. Lamotrigine as a possible cause of QRS prolongation in a patient with known seizure disorder [Case Reports]. *CJEM.* 2006;8:361–364.
- [42] Kornhall D, Nielsen EW. Failure of ketamine anesthesia in a patient with lamotrigine overdose. *Case Rep Crit Care.* 2014;2014:916360.
- [43] Kotwal A, Cutrona SL. Serotonin syndrome in the setting of lamotrigine, aripiprazole, and cocaine use. *Case Rep Med.* 2015;2015:769531.
- [44] Lu J, Xiong C, Wang X, et al. Successful treatment of severe lamotrigine and clonazepam poisoning by blood purification [Case Reports Letter]. *Blood Purif.* 2012;34:18.
- [45] Nogar JN, Minns AB, Savaser DJ, et al. Severe sodium channel blockade and cardiovascular collapse due to a massive lamotrigine overdose [Case Reports Research Support, U.S. Govt, Non-P.H.S.]. *Clin Toxicol.* 2011;49:854–857.
- [46] O'Donnell J, Bateman DN. Lamotrigine overdose in an adult [Case Reports]. *J Toxicol Clin Toxicol.* 2000;38:659–660.
- [47] Reimers A, Reinholt G. Acute lamotrigine overdose in an adolescent [Case Reports]. *Ther Drug Monit.* 2007;29:669–670.
- [48] Sbei M, Campellone JV. Stupor from lamotrigine toxicity [Case Reports]. *Epilepsia.* 2001;42:1082–1083.
- [49] Schwartz MD, Geller RJ. Seizures and altered mental status after lamotrigine overdose [Case Reports]. *Ther Drug Monit.* 2007;29:843–844.
- [50] Sethi NK, Douyon P, Kaunzner U, et al. Delayed status epilepticus due to bupropion and lamotrigine overdose. *East J Med.* 2013;18:142–144.
- [51] Sirianni AJ, Osterhoudt KC, Calello DP, et al. Use of lipid emulsion in the resuscitation of a patient with prolonged cardiovascular collapse after overdose of bupropion and lamotrigine(done) [Case Reports]. *Ann Emerg Med.* 2008;51:412–415, 415.e1.
- [52] Thundiyl JG, Anderson IB, Stewart PJ, et al. Lamotrigine-induced seizures in a child: case report and literature review [Case Reports]. *Clin Toxicol.* 2007;45:169–172.
- [53] Venkatraman N, O'Neil D, Hall AP. Life-threatening overdose with lamotrigine, citalopram, and chlorpheniramine(2X) [Case Reports]. *J Postgrad Med.* 2008;54:316–317.
- [54] Waring WS. Lamotrigine overdose associated with generalised seizures. *BMJ Case Rep.* 2009. DOI:10.1136/bcr.07.2008.0489
- [55] Weiss B, Rothmann C, Weber M, et al. Lamotrigine (Lamictal) acute poisoning: clinical and toxicokinetics correlation. [French] Intoxication aigue par lamotrigine (Lamictal): correlation toxicocinetique et clinique. *Jour.* 2002;15:208–210.
- [56] Willis T, Roper H, Rabb L. Lamotrigine poisoning presenting as seizures: a case of deliberate poisoning [Case Reports]. *Child Abuse Negl.* 2007;31:85–88.
- [57] Zidd AG, Hack JB. Pediatric ingestion of lamotrigine(2X) [Case Reports]. *Pediatr Neurol.* 2004;31:71–72.
- [58] Grosso S, Ferranti S, Gaggiano C, et al. Massive lamotrigine poisoning. A case report [Case Reports]. *Brain Dev.* 2017;39:349–351.
- [59] Hajiali F, Nassiri-Asl M. Report of severe menorrhagia following the maximum amount of lamotrigine overdose. *Iran J Pharm Res.* 2015;14:1289–1293.
- [60] Deslandes G, Bouquie R, Lorber J, et al. Status epilepticus following self-poisoning of lacosamide and lamotrigine: a case report with follow-up of drug serum concentrations. *Toxicologie Analytique Et Clinique.* 2015;27:88–90.
- [61] Veerapandiyam A, Gallentine WB, Winchester SA, et al. Oculogyric crises secondary to lamotrigine overdosage. *Epilepsia.* 2011;52:e4–e6.
- [62] Sander JW, Trevisol-Bittencourt PC, Hart YM, et al. The efficacy and long-term tolerability of lamotrigine in the treatment of severe epilepsy. *Epilepsy Res.* 1990;7:226–229.
- [63] Battino D, Croci D, Granata T, et al. Lamotrigine plasma concentrations in children and adults: influence of age and associated therapy. *Ther Drug Monit.* 1997;19:620–627.

- [64] Bartoli A, Guerrini R, Belmonte A, et al. The influence of dosage, age, and comedication on steady state plasma lamotrigine concentrations in epileptic children: a prospective study with preliminary assessment of correlations with clinical response [Article]. *Ther Drug Monit.* 1997;19:252–260.
- [65] Sorri A, Keranen T, Moilanen E, et al. The effect of oral activated charcoal on the absorption and elimination of lamotrigine. *Epilepsia.* 1998;39:53.
- [66] Keranen T, Sorri A, Moilanen E, et al. Effects of charcoal on the absorption and elimination of the antiepileptic drugs lamotrigine and oxcarbazepine [Randomized Controlled Trial Research Support, Non-U.S. Arzneimittelforschung. 2010;60:421–426.
- [67] De Lera Ruiz M, Kraus RL. Voltage-gated sodium channels: structure, function, pharmacology, and clinical indications. *J Med Chem.* 2015;58:7093–7118.
- [68] Chen HY, Albertson TE, Olson KR. Treatment of drug-induced seizures. *Br J Clin Pharmacol.* 2016;81:412–419.