

The toxicity of *Physalia physalis*: systematic review and experimental study

Elena Bañón-Boulet¹, Emilio Gonzalez-Arnay² 

¹Hospital Ship “Juan de La Cosa” Social Institute of the Marine

²University of La Laguna, Ofra, La Laguna, Spain

ABSTRACT

Introduction: Jellyfish poisonings are frequent in coastal areas of temperate latitudes. In Spain, the most frequent and dangerous jellyfish is the Portuguese man-of-war or *Physalia physalis*. Although the clinical manifestations of *P. physalis* envenomation are known, the acute management and complications are controversial, with varying criteria about proper treatment.

Materials and methods: This paper presents a systematic review of those studies that have collected clinical aspects of the sting of *P. physalis*, as well as an experimental study that evaluates the discharge capacity of nematocysts under different conditions (heated seawater at 50 °C, 4 °C seawater, distilled water, 25% commercial vinegar, distilled water, 25% commercial vinegar in seawater) as a proxy for envenomation potential including in sea lice. Also, discharged and undischarged nematocyst count was performed in air-dried tentacles at different times after specimen collection.

Results: Acetic acid does not produce nematocyst discharge when diluted in seawater and warm seawater is an optimal rinsing agent that dissolves the jellyfish mesoglea. Furthermore, the nematocysts detached from the jellyfish body maintain toxic capacity for at least 120 days after the stranding of the organism.

Conclusions: Most controversy regarding the treatment of *P. physalis* envenomation is related to the lack of proper species stratification or identification. In our sample, acetic acid does not elicit nematocyst discharge by itself, but depending on the solvent. Both vinegar and hot seawater rinses are the best first-aid treatments. A first aid protocol is proposed based on data from the review and the experimental study.

(Int Marit Health 2025; 76, 1: 42–62)

Keywords: jellyfish, sting, first-aid, vinegar

INTRODUCTION

According to fossil data, cnidarians (from the Greek „knide” = nettle) are the oldest venomous animals on Earth. They were the first to develop ways of injecting toxins into their prey some 600 million years ago, in the Ediacaran period [1].

Cnidarians are divided into several classes: *Anthozoa*, *Cubozoa*, *Hydrozoa*, *Scyphozoa*, *Myxozoa*, *Polypodiozoa* and *Staurozoa*. Among these, four are the ones that pose a danger to humans [2]:

— *Anthozoa*, which includes sea corals and anemones.

- *Scyphozoa* or „true” jellyfish, radially organized and common worldwide.
- *Cubozoa*, with a cube or box shape and tentacles at the corners. They are the most dangerous and inhabit tropical and subtropical waters.
- *Hydrozoa*. They are not true jellyfish. This group includes *Gonionemus* and *Physalia* sp.

Jellyfish arrive every year to the more than 8,000 kilometers of Spanish coastline. The most frequent are the “fried egg” jellyfish (*Cotylorhiza tuberculata*), the luminescent jellyfish (*Pelagia noctiluca*), the aquamala (*Rhyzostoma plumo*),

✉ Emilio Gonzalez Arnay, University of La Laguna, Ofra, 38200 La Laguna, Spain, e-mail: emiliogonzalezarnay@gmail.com

Received: 6.07.2024 Accepted: 29.07.2024 Early publication date: 6.12.2024

This article is available in open access under Creative Common Attribution-Non-Commercial-No Derivatives 4.0 International (CC BY-NC-ND 4.0) license, allowing to download articles and share them with others as long as they credit the authors and the publisher, but without permission to change them in any way or use them commercially.

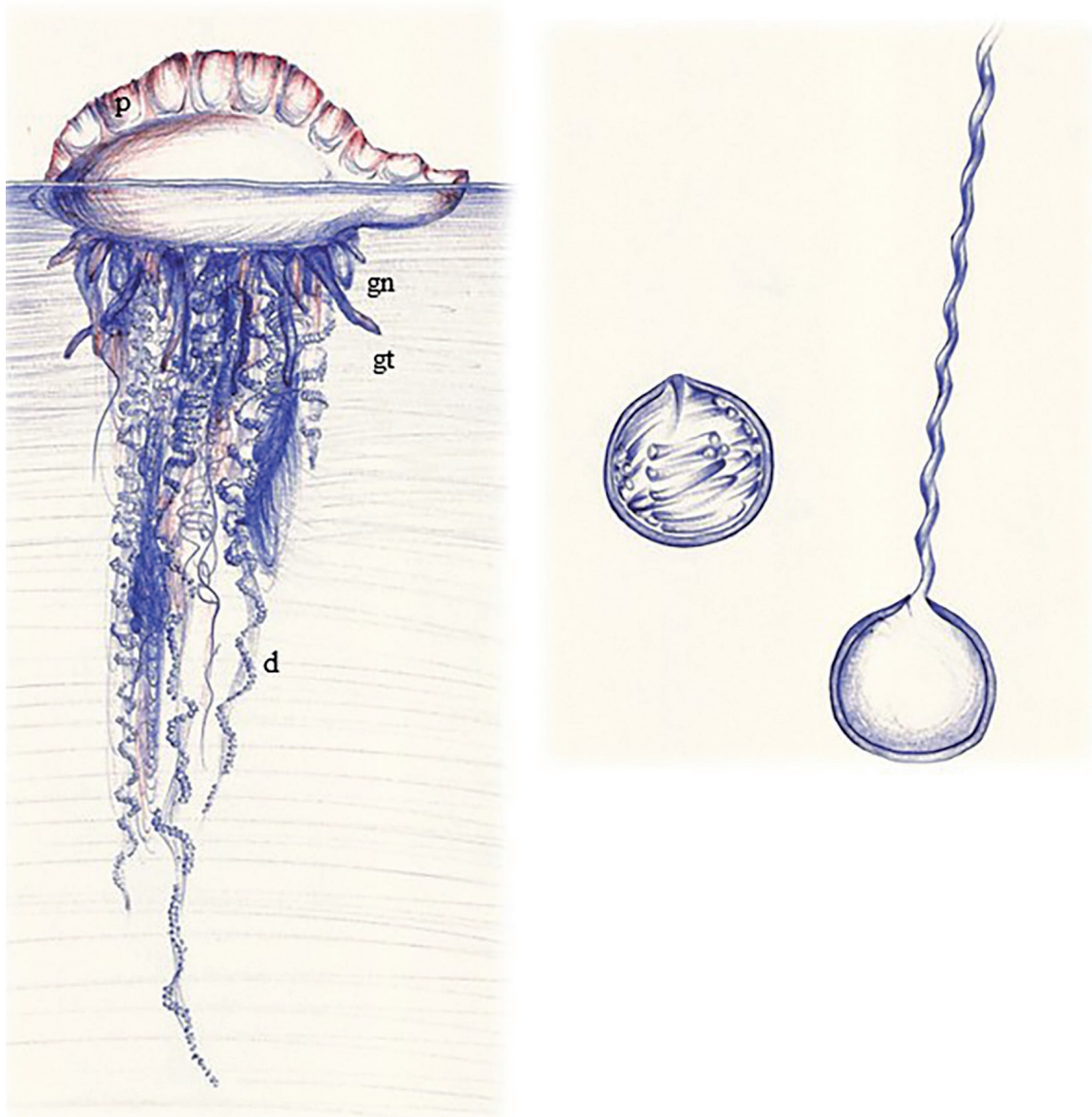


Figure 1. Drawings by Elena Bañón. A. *Physalia physalis*. Pneumatophore (p), gonozooid (gn), gastrozooid (gt), dactylozooid (d). B. nematocysts as seen under the microscope. Charged (left) and discharged (right)

the common jellyfish (*Aurelia aurita*), the “compass” jellyfish (*Chrysaora hysoscella*), the Portuguese man-of-war (*Physalia physalis*), the “little sail” (*Velella velella*), the Aequorea (*Aequorea forskalea*), the cubomedusa or “hornet” (*Carybdea marsupialis*) and the American ctenophore (*Mnemiopsis leidyi*) (source: INE, miteco.gob.es). Tourists and locals frequent the coasts throughout the year, exposing themselves to jellyfish stings. Of the above mentioned, the most worrisome is *P. physalis*, due to its high toxicity and frequent presence on beaches. *Carybdea marsupialis* is also dangerously toxic, but as it lives at depths of more than -20 m it does not usually reach the coast, except in exceptional occasions. Therefore, we will focus on the genus *Physalia*.

As previously mentioned, it is not truly a jellyfish but for clinical, practical and informative purposes it is usually treated as such. Each *Physalia* „individual” is a colony of 4 kinds of hydrozoa, each of which performs a function (Fig. 1A). One group forms the pneumatophore, a gas-filled bladder which serves as a floater and sail. The second group are the gonozooids, which produce gametes for reproduction. The third group are the gastrozooids, specialized in feeding. Dactylozooids are the long, deadly tentacles armed with nematocysts which serve a defensive function [3].

These nematocysts (also cnida) are intracellular vesicles that eject their tubules, when subjected to certain physical or chemical conditions (Fig. 1B), and inject

powerful toxins into their prey or the unfortunate bather [2]. In the case of *P. physalis*, these include phospholipase A2, phospholipase B, collagenase, elastases, PpV19.3, PpV9.4, P3, P1, physalotoxin, DNase and histamine [4]. Moreover, the mini-collagen glycoproteins and polysaccharides that form the wall of the cnida may elicit separate sensitivity responses whose intensity depends not only on the jellyfish itself but also on the victims' characteristics, including genetics [5, 6].

It is important to note that contact with the tentacles is not essential for envenomation, as free nematocysts ("sea lice") retain their activity for an unknown period of time. Cases of envenomation have even been reported after contact with nudibranchs, who store nematocysts and use them for their own defense [7].

Cnidocyte and nematocyte are synonyms, meaning the cells that contain these cnidae or nematocysts.

Physalia individuals cannot actively swim, but rather float at the mercy of wind and currents [8]. The crest or sail is tilted to different angles in some individuals as a survival mechanism, to avoid the stranding of all of them at the same time and place [2]. The genus *Physalia* includes two species:

- *P. physalis*, with a floating part up to 25 cm and long tentacles up to 30 m [9]. It is distributed in the Atlantic and Pacific oceans.

- *P. utriculus*, smaller in size, with only one long tentacle. It lives exclusively in the Pacific Ocean [10].

The incidence of *P. physalis* stings is difficult to estimate, partly because there is no worldwide registry of cases, but also because it is often difficult to determine the causative agent of a sting. After the sting, an erythema most commonly develops following the distribution of the tentacles and evolves into an urticarial rash, accompanied by burning pain and in some cases systemic symptoms. Multiple complex delayed syndromes have been published in literature, as well as isolated cases of fatal stings.

However, there is still debate about the optimal management and treatment. This is because most jellyfish sting studies do not include information stratified by species and therefore yield contradictory data. On the other hand, existing experimental studies on the discharge of *P. physalis* nematocysts under different conditions are scarce and lack internal control. Therefore, a systematic review of the literature is proposed to elucidate the specific aspects of the management of *P. physalis* stings, as well as an experimental study of the response of the nematocyst to different treatments available in the out-of-hospital setting.

OBJECTIVES

- To establish the specific aspects of the clinical evolution and treatment of the sting of *Physalia physalis*.

- To evaluate, by an in-vitro experiment, the variations of nematocyst discharge under several conditions traditionally used as first-aid measures, and at different times.
- To elaborate an updated actuation protocol for the first-aid of *Physalia physalis* stings.

MATERIALS AND METHODS

REVIEW

A literature search was performed in PubMed using the terms (jellyfish OR physal*) AND (sting OR venom OR poison*). A second search was carried out using colloquial terms: (man-of-war OR man o'war OR physal*) AND (sting OR poison* OR venom*).

A systematic review was carried out on all published cases after applying the inclusion and exclusion criteria, focusing on clinical manifestations and treatment at different stages of the disease.

Inclusion criteria:

- Articles on *P. physalis* sting.
- Clinical studies dealing with first-aid treatments for *P. physalis* stings.
- Experimental in-vitro studies dealing with first-aid treatments for *P. physalis* stings.

Exclusion criteria:

- Articles where jellyfish species is not specified.
- Articles from species other than *P. physalis*.
- Publications that do not include sting cases (guidelines, non-systematic reviews, letters to the editor, short communications, or editorial correspondence that do not include patient data).
- Experimental studies on animals other than *Homo sapiens*.
- Experimental studies that freeze, break or anyhow alter *P. physalis* toxins.
- Articles not available in English, Spanish or Portuguese.

EXPERIMENTAL STUDY

Physalia physalis colonies stranded on the coast of La Palma island were collected from January to April 2023 using long wooden tweezers and leather gloves (as nematocyst discharge can pass through nitrile gloves and thin clothes [10]) (see Annex 1). Cnidarians were kept either in glass tanks of 10 L volume each, filled with seawater, or air dried in glass containers. For the first group, water was renewed for a maximum of 48 hours. These specimens were later subject to microdissections of the stinging tentacles under a magnification glass. Three different analysis were made:

- Water stored cnidarians were tested for nematocyst discharge using different solutions.



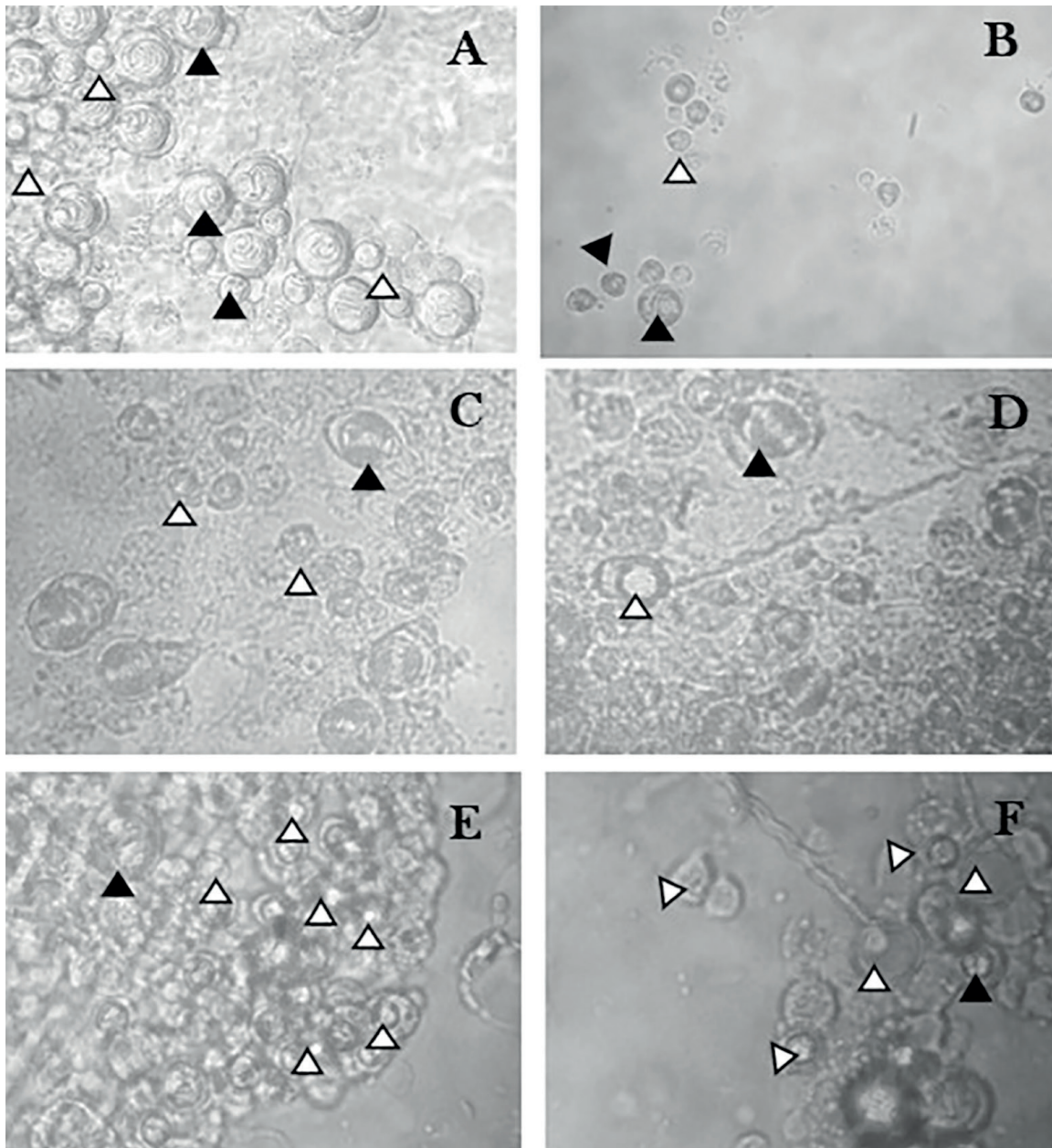
Annex 1. *Physalia physalis*. Some pictures taken during our field work

- Storing water was tested for the presence and viability of sea lice.
- Air-dried cnidarians were tested for nematocyst long-term viability in stranded colonies.

To test the response of nematocysts to different solutions of therapeutic potential, pieces of tentacles from specimens stored in seawater were dissected under a magnification glass up to a known and constant length (2 cm) before being deposited in six-well plates filled with room temperature seawater. For the analysis, inverted bright field microscopy was used on the wells. A count of intact and discharged nematocysts in four randomly selected 100X fields was performed in each well to set a baseline. Afterwards, seawater was replaced with different solutions (heated seawater at 50°C, seawater pre-cooled at 4°C for

15 minutes, distilled water, 25% commercial vinegar— circa 1% acetic acid — in distilled water, 25% commercial vinegar in seawater). After a 5 minutes-long rinsing, counting was performed again. A nematocyst was considered intact when it presented a double membrane (or a darkened one) and/or a coiled harpoon. A nematocyst was considered discharged when it suffered considerable shrinkage compared to fellow individuals, membrane and/or content was brightened, and harpoon was undetectable or partially or completely uncoiled (see Annex 2).

To test the viability and presence of independent nematocysts (“sea lice”) in storage water, 1 mL of it was subjected to 12000 rpm centrifuge during two minutes; supernatant was discharged and a fresh smear of the pellet analyzed under light microscopy before and after rinsing



Annex 2. Nematocysts as seen under the microscope on our experimental study. **A.** A 100× baseline picture of an inverted brightfield microscope showing undischarged nematocysts (black arrows) and discharged ones (white arrows). **B.** A 50× picture after rinsing in hot seawater showing a paucity of nematocysts, both discharged and undischarged. **C.** 100× picture after treatment with 1% acetic acid in distilled water. **D.** 100× picture after treatment with 1% acetic acid in seawater. **E.** 100× picture after distilled water rinsing (note the massive nematocyst discharge in the area). **F.** 100× Photomicrograph through the objective of a brightfield microscope after a smear of 48 hours old pellet of sea lice

in seawater, 1% acetic acid in seawater and 1% acetic acid in dH₂O. Criteria for nematocyst classification was the same as in the previous experiment.

To test the viability and presence of nematocysts in long stranded cnidarians, dissection, resuspension in sea water and microscopy analysis were performed in air-dried tentacles at 48h, 72 h, 8 days, 80 days and 120 days

post-stranding. A nematocyst was considered viable when it kept its original charged structure or when it appeared recently discharged. A nematocyst was considered unviable when the architecture was distorted or the capsule was empty.

Statistical analysis was performed using t-test for paired samples in SPSS 15.0.

RESULTS

REVIEW

The first literature search (24/07/2022) provided 1199 papers. A second search was made using colloquial terms on the same date and yielded 126 papers, all of which were duplicated. From these 1199, 972 were excluded basing on the information on their abstract, and 227 were selected for further reading; manual search provided additional 4 papers. After checking for exclusion and exclusion criteria, 31 papers were finally selected (Annexes 3, 4).

Case reports (Table 1)

Twenty-one isolated cases from the Pacific and the Atlantic ocean have been reported in literature, although four of them were excluded due to incomplete data. Isolated cases affected patients from a wide range of ages (4–67, mean 31 ± 19.7) with a slight predominance of females (10 vs 7). Lesions took place mostly (76%) in the limbs, and rarely in the head [11, 12] or the whole body [13]. The toxic agent was identified through direct observation in 53% of cases, while in 36% of cases the wound was attributed to *P. physalis* due to indirect data like sting appearance or known presence in the area. In two cases, serological tests were performed [14, 15].

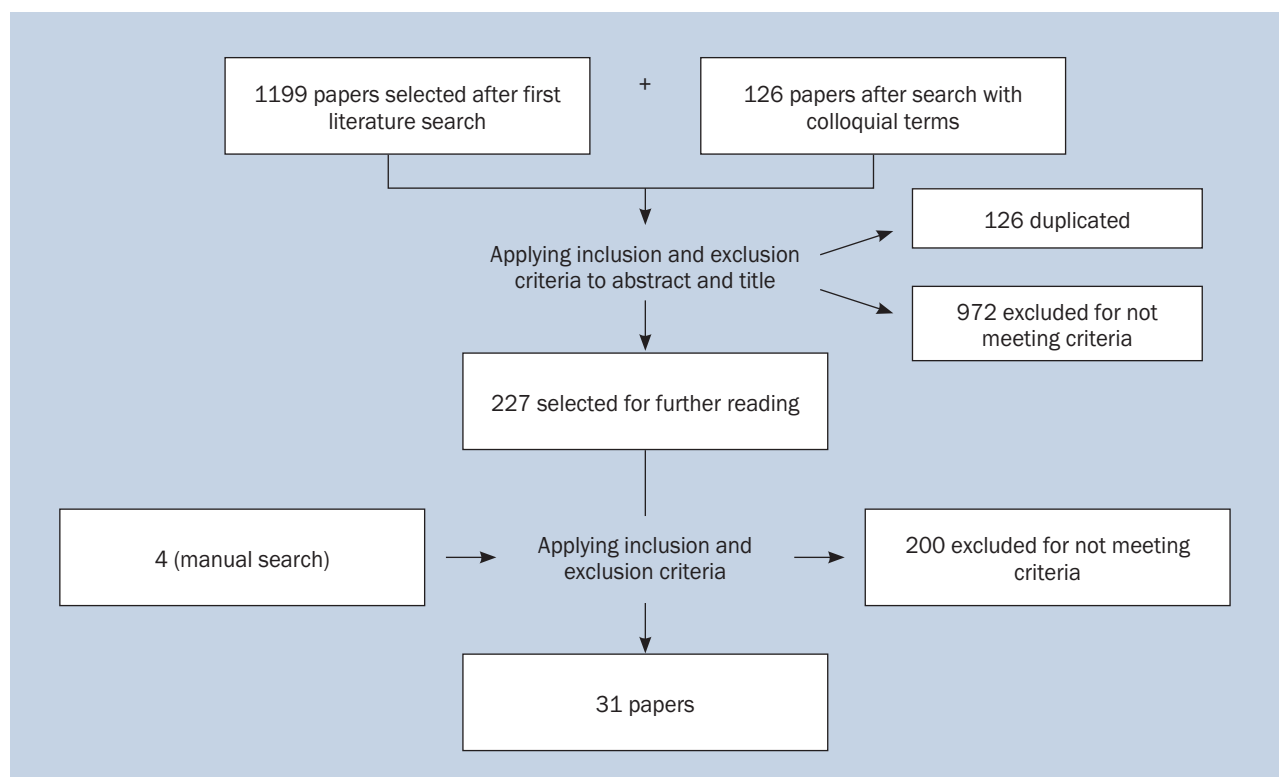
Initial symptoms (Table 1a)

All cases presented with intense stinging pain and a local skin reaction, which usually appeared as a linear,

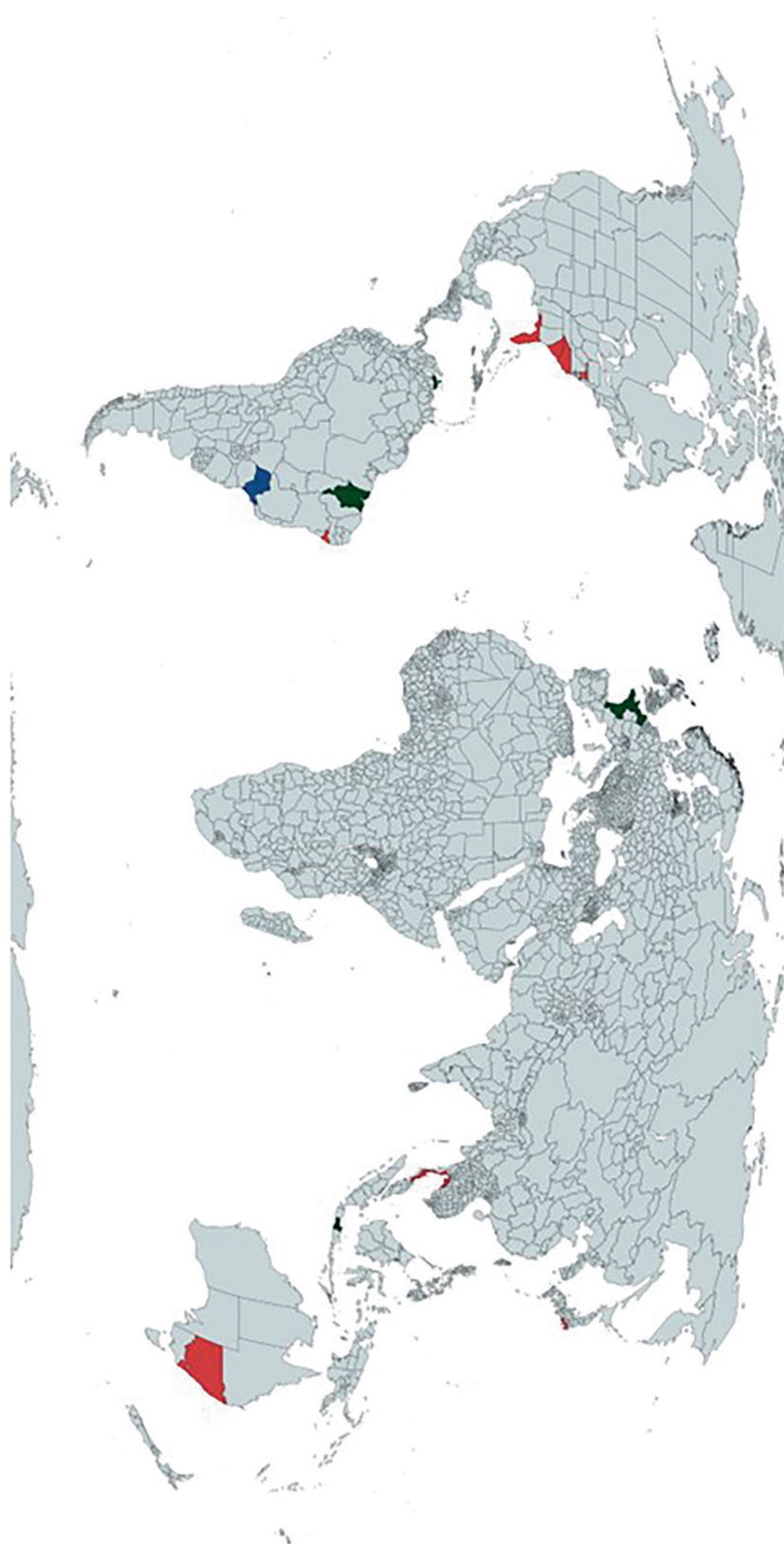
papulo-macular eruption in an erythematous background that may also adopt a purplish or even ecchymotic appearance. Macules sometimes evolved into wheals or bullae. Specific local symptoms also included mucosal swelling and blurred vision when the head was affected. Pain was almost universally described as intense and burning, as well as radiating throughout the whole affected limb. In one case, itching predominated over pain [16]. Weakness and numbness appeared immediately in the affected area in 17% of cases, including one case with dysphonia [17]; muscular cramps were also described [16, 18]. In 41% of cases, mostly associated with an absent or inadequate treatment (see Discussion), local symptoms persisted hours after the initial wound. Mild fever and/or nausea appeared in almost 30% of cases during the first day after the accident. Interestingly, grave, systemic and potentially life-threatening situations (23% of cases) appeared very early in the evolution of the intoxication, with almost immediate collapse after the sting. This includes the two deaths reported [15, 19]. An infant developing severe distress signs in the first few hours after the stinging event developed an acute kidney failure [20]. Therapeutic attitude was varied and inconsistent between cases.

Late symptoms (Table 1b)

Among all the cases described, 58% had clinical manifestations that lasted more than 24 hours. About a third



Annex 3. Flow chart from our systematic review



Annex 4. A map showing the distribution of single cases and series of cases included in this work
red — isolated case reports or series; green — bloomings; blue — both bloomings and cases

Table 1a. Case reports of acute *P. physalis* sting, early symptoms and management

Ref.	Age	Initial symptoms	Initial treatment	Initial complications	Treatment of initial complications
Asztalos et al, 2014 [23]	9	Not reported	Not specified	None	None
Auerbach and Hays, 1987 [21]	49	After 24h: cutaneous erythematous macules, local tenderness and warmth	Baking soda, meat tenderizer, isopropyl alcohol. Self-medication with erythromycin	Forever, no relief, inability to walk	Day 7 after sting: triamcinolone 0,1% cream + hydroxyzine
Burnett et al, 1987 [10]	5	Pain, lineal erythema	None	None	None
Burnett and Gable, 1989 [19]	30	Unknown	Not specified	Exitus	None
Burnett, 2005 [11]	20	Stinging pain, tongue swelling, linear papular eruption on left pectoral and deltoid, dysphonia	Topical vinegar	None	None
Chui et al, 2011 [12]	61	Swelling and blurred vision	10 min hot shower and cold compresses	Persistence of blurred vision	Chloramphenicol eyedrops 3 times a day + corneal debridement after day 3
Filling-Katz, 1984 [18]	25	Erythematous wheals with purple blotches	None	Weakness and numbness of right hand and wrist, nausea, vomiting, myalgia, sore throat, forever	None
Giordano et al, 2005 [24]	35	Puncture wound	Incision of the wound + oral penicillin	failure to recover, swelling	Ampicillin-sulbactam + levofloxacin
José Risk et al, 2012 [45]	42	Immediate pain, erythema and edema	None	Purpuric papular eruption reproducing the shape of the tentacles	Wait and see
Kajfasz et al, 2015 [16]	50	Sudden burning pain + bright red skin changes and single vesicles + induration, cramps, pruritus	Unknown	Next few days: extensive necrosis of afflicted surfaces	IV and IM antihistamines and glucocorticoids
Kaufman, 1992 [46]	14	Intense burning and pain, numbness and paralysis	70% isopropyl alcohol	Disorientation, nausea, chills, forever, diffuse pruritus and paresthesia	None
Manabe et al, 2014 [22]	7	Immediate lineal eruption and stinging pain	Topical (unspecified)	None	None
Matusow, 1980 [47]	48	Burning, swelling, erythema and ecchymosis	Ammonia	20 h after sting: severe generalized angioedema. Extreme pain. Low grade fever, malaise, nausea. Bilateral lymphadenopathy in submaxilla and neck	Oral penicillin 500 mg/6h, 10 days

Ref.	Age	Initial symptoms	Initial treatment	Initial complications	Treatment of initial complications
Spielman et al, 1982 [20]	4	Painful erythematous bullae	Dexamethasone, diphenhydramine, epinephrine and topical cortisone	Irritability (5 h later) + oliguria (0.5 mL/kg/h) + hemoglobinuria + hyperkalemia (6.8)	Mannitol diuresis + packet erythrocytes 20 mL/kg + hemodialysis
Stein et al, 1989 [15]	67	Erythematous lineal tentacle mark	None	Rapid onset of dyspnea, loss of consciousness, ECG and biochemical data of AMI, cardiorespiratory arrest	Basic CPR + multiple drugs
Russell, 1966 [13]	35	Pain, skin eruption	Fresh water shower and prednisolone isopropyl	Pain, anxiety and respiratory distress with intercostal breathing	100 mg meperidine hydrochloride + IM antihistamine + 16 mg morphine + oxygen
	28	Intense pain, linear eruption, collapse	Salt water rinse, 70% alcohol, tequila, baking powder. Steroid cream + 75 mg meperidine	Nausea, marked weakness	None

Table 1b. Case reports of *P. physalis* sting, late symptoms and management

Ref.	Late symptoms	Treatment of late symptoms	Late complications	Treatment of late complications	Evolution
Asztalos et al, 2014 [23]	Persistent erythematous itchy inflamed plaque at the site of the sting	Cetirizine and topical steroid ointment for 3 weeks + tacrolimus ointment 4 weeks	Relapse of the lesion without tacrolimus	Reassuming tacrolimus + intralesional triamcinolone acetate 10 g/L	Clinical remission at the time of publication
Auerbach and Hays, 1987 [21]	No improvement	IM tetanus toxoid, dexamethasone + oral methylprednisolone (two cycles)	Joint pain, subcutaneous nodules	Indomethacin (unresponsive) and high dose prednisolone	Favorable after high dose prednisolone, follow-up loss
Burnett et al, 1987 [10]	8 days: Pruritus, exacerbation of edema, urticaria, flesh colored ulnar papules	Topical steroids	None		Full recovery after 3 days of treatment
Burnett and Gable, 1989 [19]	Not applicable				Exitus
Burnett, 2005 [11]	None				Dysphonia receded after 30-45 min, pain after 1 h, and eruption after 24 h
Chui et al, 2011 [12]	None				Full recovery
Filling-Katz, 1984 [18]	Diffuse weakness and numbness	Wait and see	None		Full remission after 2 and a half months
Giordano et al, 2005 [24]	Cyanosis, coolness, induration, continued pain. Absence of pulse.	Debridement and iv gentamycin, vancomycin and metronidazole	None		Full recovery
José Risk et al, 2012 [45]	None				Fading after a week, full recovery in a month
Kajfasz et al, 2015 [16]	Muscular contraction + leg swelling	Rehabilitation	Disfiguring scars. Hyperesthesia and paresthesia up to 5 months	Long term rehabilitation	Swelling of left leg persists at present
Kaufman, 1992 [46]	None				Easing of pain after 6 h, full recovery
Manabe et al, 2014 [22]	(3 months) Persistent eruption + lymph node swelling	Topical steroid + antiallergic	None	None	Protracted course over 16 months despite continuous treatment
Matusow, 1980 [47]	None				Progressive remission
Spielman et al, 1982 [20]	None		Fever and abdominal distention after peritoneal dialysis	Abandonment of dialysis	Complete restoration of kidney function after 30 days
Stein et al, 1989 [15]	None		Aspiration pneumonia	Ventilator support	Exitus after 5 days
Russell, 1966 [13]	Soreness in large muscle muscles and wheals	None	None		Hyperpigmentation for 3 weeks after the stinging. Full recovery
	Headache 8 h after; soreness in the neck, chest and back	None	None		Regained consciousness in minutes. Full recovery in 4 days, maintaining hyperpigmentation

of published cases suffered from a protracted (from 48 hours to several weeks) course of skin lesions, mainly behaving as erythematous or flesh-colored macules to plaques affecting the site of the initial wound accompanied by local or generalized urticaria [14, 21–23]. These lesions may evolve into an erythema nodosum-like subcutaneous nodule. These kind of protracted skin wounds were associated to a lack of proper first-aid measures and did not respond well to mere topical treatments with antihistamines or steroids. Nodular, long-term, lesions required aggressive treatments (tacrolimus ointments and high-dose corticosteroids, either intralesional or systemic). Weakness, soreness, and numbness of the muscles in the affected limb, that may also appear as an early symptom, were present as a late symptom in 23% of the described cases and tended to self-resolution. In one case [16], the affected limb followed a very torpid evolution being left with persistent pain and disfiguring scars (see Discussion). When this kind of torpid evolution appears in the first hours of envenomation, an ischemic process due to vascular spasm of compartmental syndrome may be under way [24], paving the way for surgical treatments. Both initial and delayed symptoms are shared by many jellyfish envenomation syndromes [25].

Case series (Table 2)

Four studies were included which described series of cases of *P. physalis* stings, usually in the context of blooming or massive strandings [3, 26–28]. The biggest number of cases informed in a single study came from the Indonesian city-province of Yogyakarta and the neighboring coast, with 1287 events, but provided few to none clinical data and was therefore excluded [29].

Two of the studies relied in expert identification of envenoming agents [26, 27] while the other two [3, 28] attributed to *P. physalis* all the stinging events during a known episode of blossoming. In these large series of cases, median age of patients was significantly lower and males predominated over females compared to isolated case reports. As in single case reports, limbs were the most frequent affected areas, always in the form of a linear skin lesion. Roughly 30% of patients were treated with acetic acid in various formats and the rest with seawater rinsing and tentacle removal assisted by shaving cream [27]. First-aid measures appeared to yield positive results as only 4.6% of victims presented enduring symptoms that were treated with acetaminophen, corticosteroids and benzodiazepines [27], or intramuscular metamizole [28]; 4.5% of patients presented mild general malaise and 8.6% gastrointestinal symptoms. Severe complications were rare but not exceptional, with 4.7% of all patients suffering from dyspnea and 2.5% of patients suffering from cardiovascular malaise including one case of shock [3]; hydrocortisone 5 mg/kg was used

in one study for cases of suspected laryngeal edema, with apparent success [26]. Overall, all but one cases ([28]; no further details) achieved full recovery, albeit 3.6% of patients suffered from permanent dermal marks. Median duration of local pain was 4 hours [27], with some reduction in cases where acetic acid was used [28].

Experimental studies on treatment (Tables 3, 4)

Eight clinical studies (Table 3) and three in-vitro studies (Table 4) were included. Among the clinical studies, four consisted of single-patient assays. Three of them were self-experiments conducted by the author. All experiments yielded negative results regarding topical sunblock, concluding that it did not prevent the development of skin lesions after the sting, while cold water after the attack seemed to increase pain and warm water seemingly increased lymphatic spread. Sand rubbing, ammonia and warm water did not provide significant symptom relief. Although individual studies using warm or mildly hot water provided no differences, large, randomized studies ($n = 96$ in Loten et al., 2006 [30] and $n = 54$ in Bowra et al., 2002 [31]) have provided good quality evidence of the usefulness of hot water (as hot as can be tolerated) compared to cold for both general symptoms and local pain. Local skin reactions took place independently of treatment. A shorter, older, randomized study also supported vinegar and Stingose® as pain relief agents [32]. A single study [33] found some role for local ice packs; however, it was an uncontrolled study that only provided results in a qualitative and rather vague format.

Only three experimental in-vitro studies have evaluated the effect of first-aid treatments, using different approaches: qualitative or quantitative analysis of cnidae discharge [34, 35] and an envenomation model [36] that used a blood-agar preparation as both a stinging surface to evaluate cnidae discharge and a proxy for the toxin cytolytic effect. The most recent one showed that vinegar and Sting-no-more® solutions prevented pressure-induced discharge, arguably the most likely mechanism of human envenomation. Also, although seawater on itself did not change the ability for discharge, heat in any form (including heated seawater) reduced the hemolytic halo in the preparation. Results regarding vinegar are contradictory as it was found [34, 35] to be among the chemicals that elicited immediate nematocysts discharge. This issue will be later expanded in the Discussion.

EXPERIMENTAL STUDY

The first and major aim of this study was to determine the suitability of different proposed therapeutic solutions to elicit discharge of the nematocysts of specimens of *P. physalis* stranded in Canarian coasts during the winter and early spring of 2023. Episodes of *P. physalis* strandings took

Table 2. Case series of *P. physalis* sting

Ref.	Country	Sex	Age	Initial symptoms	Location	Initial treatment	Initial complications	Treatment of initial complications
Cazorla-Perfetti et al, 2012 [26]	Venezuela	35 M, 24 F	NS	59 linear erythematous plaques, 11 dyspnea + laryngeal edema + fever, 7 general malaise, 5 local edema + papules + macules, 2 tachycardia	NS	acetic acid 4% (for all), hydrocortisone iv 5 mg/kg or 500 mg (for laryngeal edema)	Not described	
		40 25 M, 15 F	18	All: Intradermal edema along the tentacle path. 4 respiratory distress; 4 NRL symptoms; 4 musculoskeletal; 1 gastrointestinal symptoms	NS	Rinse with sea water and removal of tentacles with shaving cream (all)	Severe pain in 4	Acetaminophen, corticosteroids and benzodiazepines
Labadie et al, 2012 [27]	France (Atlantic coast)	154 97 M, 57 F	14	154 intradermal edema along the tentacle path. 8 respiratory distress; 42 nrl symptoms; 39 musculoskeletal; 29 gastrointestinal	NS	Rinse with sea water and removal of tentacles with shaving cream (all)	Severe pain in 11	Acetaminophen, corticosteroids and benzodiazepines
		885 525 M, 360 F	13	885 intradermal edema along the tentacle path. 44 respiratory distress; 53 nrl symptoms; 70 musculoskeletal; 71 gastrointestinal	NS	Rinse with sea water and removal of tentacles with shaving cream (all)	Severe pain in 88	Acetaminophen, corticosteroids and benzodiazepines
Haddad Jr et al, 2013 [28]	Brazil	331 210 M, 121 F	n.s	100% linear erythematous plaques with a rosary-like pattern, cold sweats (54), vomit and nausea (33), tachycardia (24), chest pain (3)	upper limbs (126), lower limbs (90), chest (81), abdomen (24), chest and hands (45), multiple (63)	Acetic acid 4–8% and cold marine water compresses in 279	16 children continued with pain	IM dipyrone (16)
Bastos et al, 2017 [3]	Brazil	89 No data	No data	71 erythema, edema and linear plaques; 14 vesicles; 12 palpitation, anxiety and irritation; 9 general symptoms; 7 dyspnea; 1 shock	20 legs; 19 hands; 15 arms; 11 abdomen	Acetic acid + sulfadiazine in most of them (not specified)	No data	

NS — not specified; IM — intramuscular; NRL — neurological

Table 3. Clinical experimental studies related to treatment of acute *P. physalis* sting

Ref.	Type	N	Intervention	Endpoint	Results	LoE
Burnett, 2005 [19]	Single case experimental study	1	Topical sunblock (Safe Sea) vs untreated skin, then self-inflicted sting	Development of skin lesions	No difference	4
Loten et al, 2006 [30]	RCT	96	Hot water (HW) immersion vs ice packs (IP) after <i>Physalia</i> sting	Symptoms	87% HW vs 33% IP local pain reduction. Incidence of 10% (HW) vs 30% (IP) radiating pain, 2% vs 6% generalized pain, 4% vs 1.1% nausea, 43% vs 41% itchiness, 43 vs 41 minor rash, 19% vs 27% raised reaction, 3% vs 2% bullous reaction	2
Bowra et al, 2002 [31]	Randomized crossover trial	54	Hot showers vs cold pack application after <i>Physalia</i> sting	Pain reduction	Hot showers reduced total treatment time (11 min vs 14.5 min) and led to greater pain reduction (82.1% vs 65.5%). Complete pain cessation: 48% in hot shower vs 29% with ice packs	2
Exton et al, 1988 [33]	Uncontrolled trial	143	Ice packs 5–10 min. If pain persisted, again ice pack for 5–10 min	Pain reduction	All of the mild pain cases resolved after 1 application. 1/4 moderate and 1/3 severe pain required additional treatment	4
Bennett, 1834 [48]	Case history	1	The author stung himself, then applied cold water	Symptoms	Cold water application seemed to increase symptoms	4
Barnes, 1965 [49] (in Cleland and Southcorreds)	Case history	1	Sting was treated by rubbing dry sand and with a weak ammonia solution. 1 h later the boy returned to water. Then treated the sting with ice and warm water	Symptoms	Sand and ammonia seemed to have no effect. Pain was worsened 4.5 h after the sting when rubbing the area with ice. Warm water had no effects.	4
Burnett, 1989 [14]	Case history	1	31 °C water bath for 13 min following a <i>Physalia</i> sting	Symptoms	Visible erythematous lymphangitic spread appeared after treatment	4
Turner and Sullivan, 1980 [32]	RCT	20	Four-arm trial: 4 stings per participant (2 x arm). Vinegar, methylated spirits, Stingose or salt water were applied 2 min after the sting for an unknown duration	Pain, skin reaction	Methylated spirits increased pain in comparison with sea water. Vinegar and Stingose reduced pain	4

RCT – randomized controlled trial

Table 4. Experimental studies related to the treatment of acute *P. physalis* sting

Ref.	Approach	Endpoint	Results
Burnett et al, 1983 [34]	Discharge model	Qualitative cnidae discharge	Clorox®, vinegar, acetone and ammonia caused nematocysts discharge. Vinegar blocked nematocyst discharge caused by Clorox® and 0.1 N Na(OH). Baking soda prevented nematocyst discharge caused by vinegar or ammonia
Birsa et al, 2010 [35]	Discharge model	Absolute numbers of cnidae discharge	Solutions of acetic acid, ethanol, ammonia and bromelain resulted in the immediate discharge of numerous nematocysts. Lidocaine inhibited discharge by other chemicals
Wilcox et al, 2017 [36]	Envenomation model	Percentage of cnidae discharge	Fresh water, urine, pressure and ethanol promote cnidae discharge. Vinegar and Sting-no-more spray prevent pressure-induced discharge. Sea water does not preclude pressure-stimulated discharge

place immediately after the low tide in warm days of winter (20–25°C maximum – 15–20°C minimum); these conditions arise cyclically when strong winds directed from southeast to northwest predominate and are usually associated with the presence of dust particles in the atmosphere. This combination of factors allowed to choose the most suitable days and places for specimen recovery, that took place in Eastern-facing sandy or low-lying shores of the Island of La Palma (Playa de Nogales, Puntallana and La Salemera, Mazo). Only specimens directly observed at the time of stranding were recovered. Glass tanks containing the specimens (in seawater) were transported to the laboratory of Pathology of the General University Hospital of La Palma where they were classified and divided into two groups. The first group was kept in fresh seawater to perform the test while the other group was left to dry in glass containers.

The tests were performed in well plates, where four different tentacles from four different colonies were floated. As the mere mechanical stress during transportation may induce a fair degree of nematocyst rupture or discharge, a “baseline” condition was set for each tentacle by quantifying the absolute number of intact (using four random 100X fields) and discharged nematocysts and calculating the ratio, which was 0.51 ± 0.07 overall. Afterwards, seawater was gently removed with a Pasteur pipette and replaced with heated seawater at 50°C, pre-cooled seawater, distilled water, 25% commercial vinegar – circa 1% acetic acid – in distilled water, or 25% commercial vinegar in seawater – circa 1%. After 5 minutes rinsing, the liquid was removed and the ratio between intact and discharged nematocysts was calculated again for each tentacle (Table 5).

After testing the parametrical nature of the samples (Kolmogorov-Smirnov test: $Z = 0.62$, sig = 0.824 for baseline group; $Z = 0.53$, sig = 0.938 for cooled water group; $Z = 0.62$, sig = 0.830 for heated water group; $Z = 0.57$, sig = 0.9 for acetic acid in distilled water; $Z = 0.82$, sig = 0.51 for acetic acid in seawater; $Z = 0.98$, sig = 0.975 for distilled water), a Student t-test for paired samples was performed for each well, comparing the ratio of discharged

nematocysts before and after the 5-minutes long rinse in the “treatment” solution (Fig. 2, Table 6). Results show no difference in nematocyst discharge when the sample is subjected to any seawater-based dilution, including a 1% acetic acid one ($t = 0.139$, sig = 0.898 for cooled seawater, $t = -0.867$, sig = 0.45 for heated seawater; $t = 0.358$, sig = 0.744 for acetic acid in seawater). However, both distilled water and 1% acetic acid in distilled water elicited significant cnidae discharge ($t = -5.056$, sig = 0.015 for acetic acid; $t = -4.193$, sig = 0.025). Interestingly, the treatment with hot water did not elicit nematocyst discharge but induced a significant loss of nematocysts in the assay well which is related to an almost complete dissolution of the extracellular scaffold of the tentacle (see Discussion).

Although theoretically the most suitable way to transport specimens of cnidarians, confinement in large seawater-filled containers resulted in an almost immediate change of behavior of the colonies. Freshly recovered specimens tended to inflate the pneumatophore when deposited into the jar and extended their tentacles until contacting with the walls and bottom surface of the container. However, this behavior lasted very few minutes and was rapidly replaced by a gradual detachment of tentacles that transformed the liquid into a bluish solution with notable stinging ability (see Annex 5). This behavior was repeated after any change of transporting medium and, thus, it does not appear to be an agonic phenomenon. This bluish water was full of sea lice that remained both in an intact and discharged status at both 24 and 48 hours after specimen stranding (38.6/ mL at 24 hours, 27% of nematocysts discharged; 80.6/ mL at 48 hours with 31% of nematocysts discharged). Smears of sea lice were tested for reactivity against distilled water and 1% acetic acid in distilled water. At 24 hours both distilled water and acetic acid 1% in distilled water elicited a fair degree of cnidae discharge (63% and 58%); cnidae were unresponsive to hot sea water and acetic acid diluted in seawater. At 48 hours, nematocysts maintained their reactivity (63% discharge in distilled water and 80% discharge in acetic acid).

Table 5. Ratio of discharged nematocysts before and after rinsing with potentially therapeutic solutions used for the treatment of acute *P. physalis* sting

Well	Total nematocysts	Discharged nematocysts	Total nematocysts	Discharged nematocysts	Ratio	Arithmetic mean
Well-1	Baseline		Cooled Seawater			
	160	88	181	94	0.52	
	29	14	99	42	0.42	
	152	72	92	50	0.54	
	81	34	81	33	0.41	0.47 ± 0.07
Well-2	Baseline		Heated seawater			
	73	39	22	13	0.59	
	55	36	12	7	0.58	
	52	26	12	4	0.33	
	86	46	55	40	0.73	0.56 ± 0.16
Well-3	Baseline		Acetic acid 1% in dH ₂ O			
	89	54	32	21	0.66	
	94	45	106	78	0.74	
	82	40	90	60	0.67	
	90	51	78	42	0.54	0.65 ± 0.82
Well-4	Baseline		Acetic acid 1% in Seawater			
	65	36	67	26	0.39	
	36	17	35	14	0.40	
	43	29	34	13	0.38	
	55	25	37	23	0.62	0.45 ± 0.12
Well-5	Baseline		dH ₂ O			
	68	35	55	40	0.72	
	63	29	45	27	0.60	
	134	52	30	21	0.70	
	23	13	50	39	0.78	0.70 ± 0.76
	Baseline arithmetic mean					
	0.51 ± 0.07					

As a complementary trial, the viability of nematocysts from tentacles of colonies that were stranded long-time ago was tested.

Dried tentacles were difficult to distinguish from dried gastrozooids and gonozooids and therefore most smears provided no results. However, after a careful examination, all the results were positive for nematocyst viability (48 h, 72 h, 8 days, 80 days and 120 days post-stranding, although as time passed the percentage of viable vs unviable nematocysts tended to decrease.

DISCUSSION

The *Physalia physalis* or Portuguese-man-of-war (in Spanish *carabela portuguesa*, also *aguaviva/aguamala*) is the most common toxic jellyfish in Spanish coastal waters, where massive strandings are seasonal and cyclical.

The present work is the first review focused exclusively on clinical aspects that are specific of *P. physalis*. Previous works in the field sort together data arising from stinging events caused by other cnidarians (frequently including the dangerous *Chironex fleckeri*, which is not present

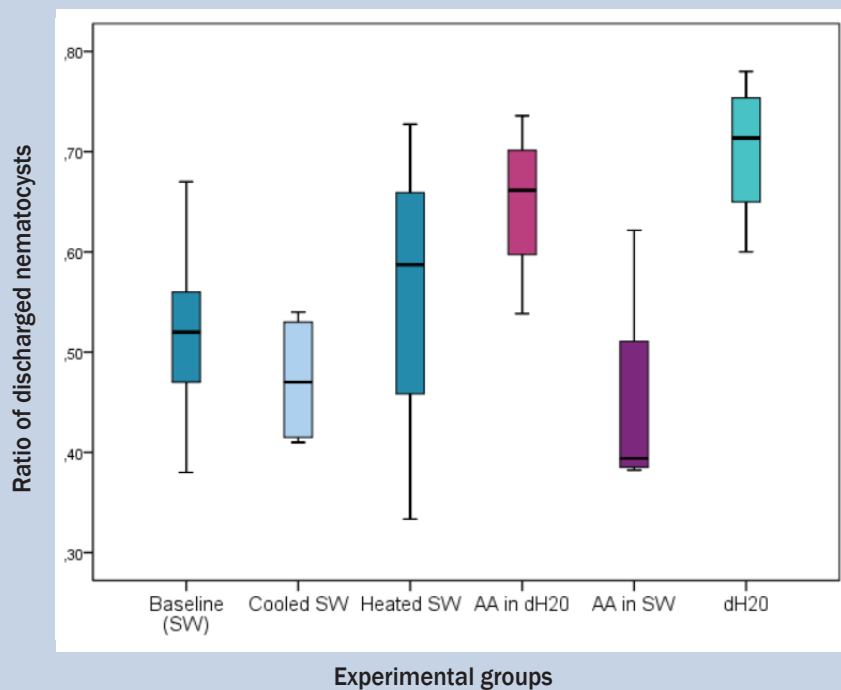


Figure 2. Graphic of t-test results. Ratio of discharged nematocysts in different experimental groups. SW (seawater), AA (acetic acid), dH2O (distilled water)

Table 6. Results of t-test for paired samples

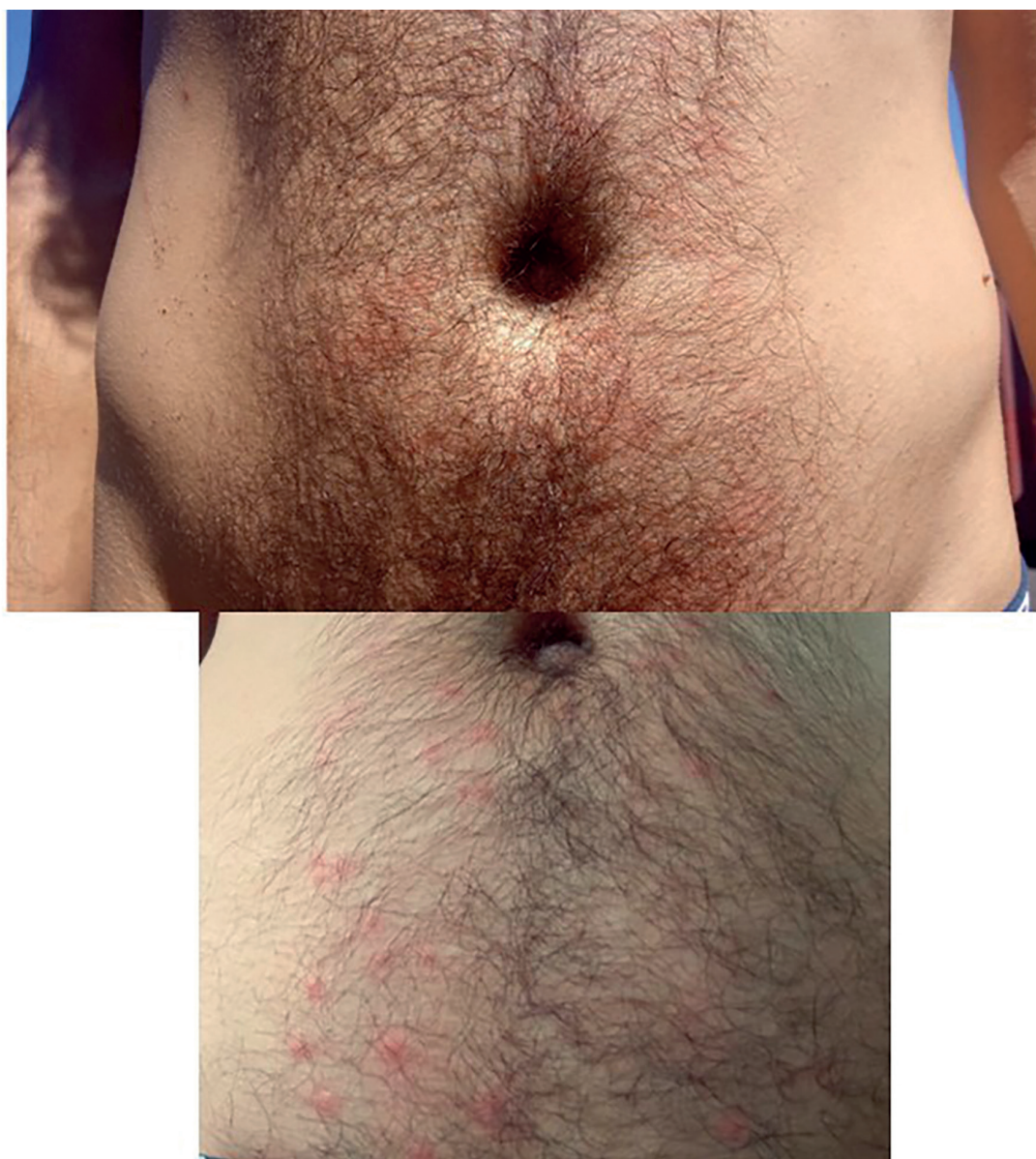
Comparison	Mean	SD	St. error	Confidence interval (95%; lower to upper limit)		t	DF	Sig.
Baseline-Cooled seawater	0.00388	0.05596	0.02798	-0.08516	0.09293	0.139	3	0.898
Baseline-Heated seawater	-0.08121	0.18736	0.09368	-0.37934	0.21692	-0.867	3	0.450
Baseline-Acetic 1% in dH2O	-0.17181	0.06796	0.03398	-0.27995	-0.06366	-5.056	3	0.015
Baseline-Acetic 1% in SW	0.02949	0.16494	0.08247	-0.23296	0.29194	0.358	3	0.744
Baseline-dH2O	-0.22432	0.10701	0.05350	-0.39459	-0.05405	-4.193	3	0.025

SD – standard deviation; DF – degree of freedom

in Atlantic waters) or, at best, from the genus *Physalia* altogether, which includes the smaller *P. utriculus*, non-existent in Atlantic and Mediterranean coasts. Therefore, a focused review may help to clarify the true severity of *P. physalis* stinging events and provide emergency protocols for first aid and follow-up of patients; this is relevant mostly because treatments are usually species-specific. However, our strict inclusion criteria may risk excluding noteworthy studies, particularly cases where the toxic agent remained unidentified but resulted in delayed complications, mostly of cutaneous or vascular nature [37]. A strong limitation of our experimental study is that the approach measures

the number of nematocysts released but does not quantify the degree of activity of the toxin. Also, proper follow-up of the toxicity of sea lice and stranded tentacles has been hampered by the protocols followed for transportation, storage and resuspension.

The experimental study here described, despite its limitations, shows some interesting results. The most important one is the fact that a dilution of commercial vinegar in seawater does not elicit nematocyst discharge. Nematocysts of *Physalia* genus respond to changes in water osmolarity, pressure and certain chemicals [34, 35]. Laboratory studies carried in different species of cnidarians have included



Annex 5. Stings of sea lice. A brave volunteer, who prefers to remain anonymous, stung himself on the belly with bluish water from the glass tanks, full of nematocysts. The first picture was taken 10 min after contact with water, and the second one 12 h after. Note the erythema in the first picture, and its evolution into punctiform lesions

acetic acid among the chemicals that produce cnidae discharge. These findings have even led to the proscription of the use of vinegar as a first-aid measure in many guidelines [16, 38], which contradicts previous studies [32] and folk culture in places where *Physalia* stings are frequent. Results here presented show that vinegar does not produce discharge by itself, and discharge is related to the solvent. Indeed, the ability for discharge in the presence of an acetic acid 1% solution in distilled water is similar to the recorded discharge in distilled water. Thus, the osmotic shock caused by the non-saline nature of the water used as a solvent for commercial vinegar is the most likely cause of the discharge, and not the chemical by itself. This

reinforces the findings of Burnett and colleagues [34], who found that vinegar was able to block chemical-induced discharge. As for the ability of acetic acid to relieve pain regardless of nematocyst discharge, our review is once again in accordance with folk tradition. Data here presented are similar to what is described for *Carybdea marsupialis*, but not *Pelagia noctiluca* and scyphozoans (see work by Ballesteros et al [39–41], sharing experimental approach with ours). Therefore, species identification is necessary for an adequate management.

There is another traditional remedy strongly supported by literature [30, 42] and that is the use of hot seawater. In our experimental model, hot seawater treatment does not

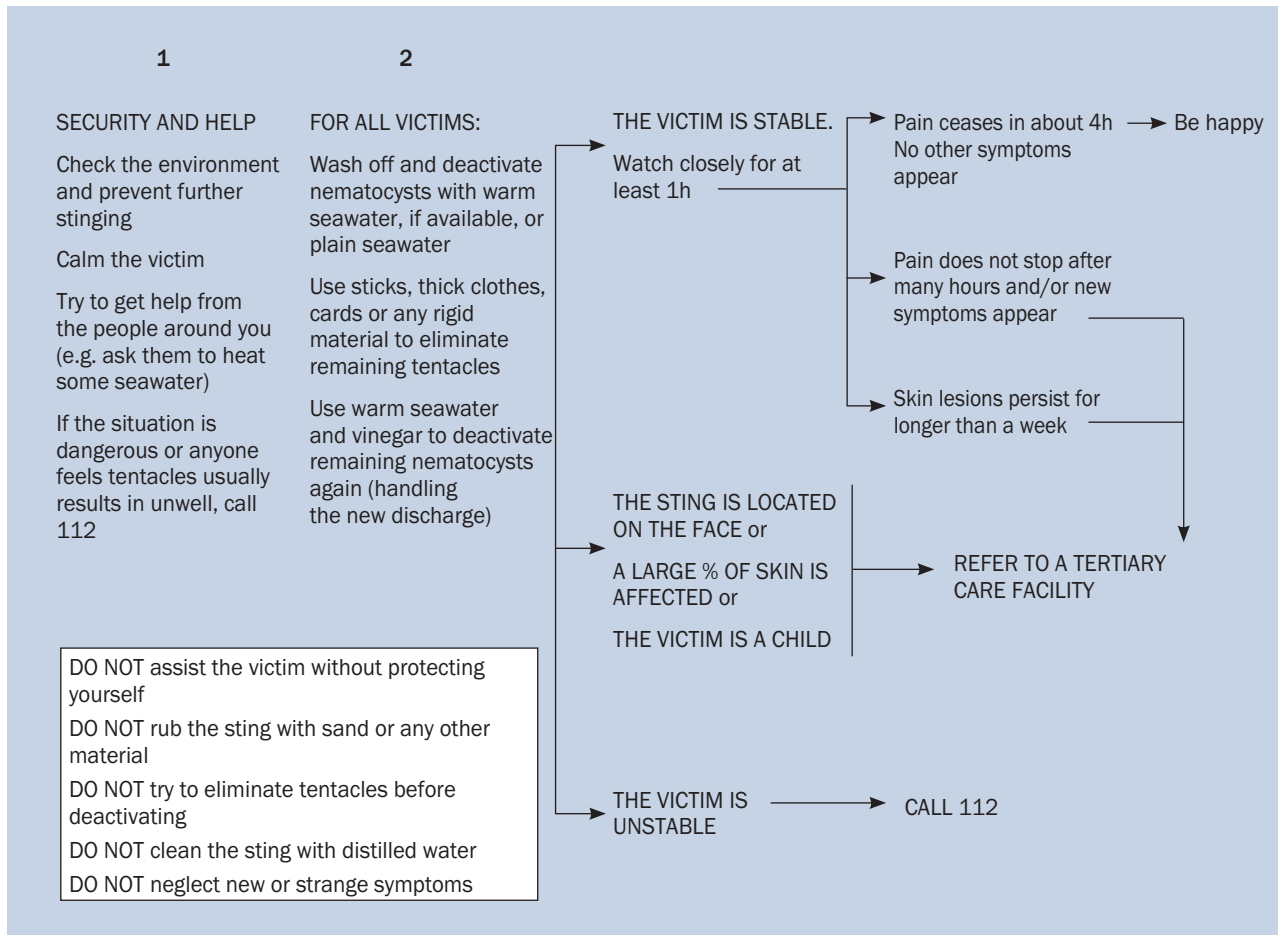


Figure 3. Suggested protocol for first-aid assistance of *P. physalis* stings

produce discharge and indeed washes away the nematocysts from the tentacle, being mere dilution the most likely effect of hot water in pain alleviation after an envenomation. The most suitable mechanism for this effect is the dilution of the interindividual matrix that holds together the colony, called the mesoglea, which is rich in water-soluble proteoglycans [43]. Therefore, despite the reported easing of lymphatic spread, our experimental data reinforce the already established usefulness of hot seawater showers as a first-aid measure. Moreover, *P. physalia* venom is known to be a heat labile toxin [2], which may also explain the clinical improvement after hot water is applied. Altogether, both hot showers and vinegar rinsing should be regarded as the primary first-aid measures.

Another relevant result that arises from both the experimental study and the field experience is the fact that the liberation of nematocysts in the form of sea lice appears to be a standard “behavior” of *P. physalis* colonies when confined, perhaps as a mechanism to guarantee the survival of part of the colony after getting trapped in shallow intertidal waters.

Sea lice can survive intact and maintain their ability to sting at least after 48 hours in backwaters. Therefore, a stinging event by *P. physalis* may happen even in the absence of full-fledged colonies and skin lesions may not necessarily adopt the classical form of an erythematous rosary-like chain of papules; sea lice and desiccated tentacles are the likely cause of some amount of the “swimmers’ rush”, at least in our context. This fact also bears epidemiological relevance, as a previous immunization (even if unnoticed by the patient) may underlie an immediate or retarded hypersensitivity reaction after a stinging event or after the consumption of dried jellyfish as a meal [44]. We propose that any case of “swimmer rush” might be treated as a *P. physalia* sting for first-aid measures, at least in a compatible context.

Dried-off tentacles have been shown to contain viable nematocysts, albeit in a more limited amount, at least 120 days after stranding. Although we could not assess nematocyst viability over 120 days, we believe that it is very probable they maintain their activity for many months more, partly due to personal experience. The 120-day milestone,

however, has an importance on its own, as it is the first time it gets objectively measured and reported in literature.

Data from clinical studies and case reports show some noteworthy patterns:

- The primary lesion is normally a painful erythematous eruption with marked dermal edema that follows the trajectory of the tentacle.
- Initial skin lesions may evolve into an urticariform eruption or even a nodosum-like erythema.
- Median duration of pain is around 4 h or even less if adequate measures are taken; cases of severe pain (particularly when associated to muscular cramps) may herald a severe vascular complication leading to member ischemia due to compartmental syndrome and vasospasm.
- *P. physalis*, contrary to common belief in some areas, may produce fatal envenomation. Severe, potentially life-threatening reactions always happen in the first minutes after the stinging event and their onset may be sudden or preceded by dyspnea. These events are related to a potentially “hidden” hypersensitivity — highlighted by the fact that they show immediate response to epinephrine and volume expansion [5] — but also to the possibility of the toxin causing rapid vascular reactions and collapse in the same way as the Irukandji syndrome, which is mostly (albeit not exclusively) associated with *Carukia barnesi* [2].
- Both hot seawater showers and vinegar rinses are useful first-aid measures.

Altogether, the systematic review and the experimental results provide a basis for the elaboration of a protocol for the assistance of patients attacked by *P. physalis* (Fig.3).

CONCLUSIONS

- The primary lesion of *P. physalis* sting is a rosary-like papular eruption over an erythematous background. This can evolve into urticarial or nodular chronic eruptions. Cramps and general symptoms may appear in the first few hours. Protracted pain and muscular cramps may herald of vascular complications.
- Acetic acid does not elicit nematocyst discharge by itself, but depending on the solvent. Both vinegar and hot seawater rinses are the best first-aid treatments.
- Toxicity of nematocysts is maintained in isolated ones (sea lice) and dried tentacles for at least 120 days after the stranding of the “parent” colony, producing skin lesions divergent from the canonical one.

ARTICLE INFORMATION AND DECLARATIONS

Data availability statement: Any additional information required is available under request to any of the authors.

Ethics statement: The study was carried out in accordance

with the requirements expressed in the Declaration of Helsinki and the Laws and Regulations in force in Europe and Spain. In our case information sheet or informed consent was not needed, as all data collected in the systematic review is anonymous. The study received approval by the local ethic committee reg. CEIBA 2023/3255.

Author contributions: EGA designed the experimental study. EBB performed the systematic review and elaborated the figures. Both authors participated in the field work, experiments, and elaboration of the manuscript.

Funding: No funding received for the study

Acknowledgments: We are thankful to laboratory of Pathology the University Hospital of La Palma and Eduardo Salido Ruiz (University of La Laguna) for their technical advice.

Conflict of interest: This is an original work. Its results have been presented as a degree thesis by EBB in the Autonomous University of Madrid. Authors declare no conflict of interest.

Supplementary material: Annexes 1–5.

REFERENCES

1. Starcevic A, Long PF. Diversification of animal venom peptides—were jellyfish amongst the first combinatorial chemists? *Chembiochem*. 2013; 14(12): 1407–1409, doi: 10.1002/cbic.201300305, indexed in Pubmed: 23821453.
2. Ottuso P. Aquatic dermatology: encounters with the denizens of the deep (and not so deep) a review. Part I: the invertebrates. *Int J Dermatol*. 2013; 52(2): 136–152, doi: 10.1111/j.1365-4632.2011.05431.x, indexed in Pubmed: 23347300.
3. Bastos DM, Haddad V, Nunes JL. Human envenomations caused by Portuguese man-of-war (*Physalia physalis*) in urban beaches of São Luis City, Maranhão State, Northeast Coast of Brazil. *Rev Soc Bras Med Trop*. 2017; 50(1): 130–134, doi: 10.1590/0037-8682-0257-2016, indexed in Pubmed: 28327816.
4. D’Ambra I, Lauritano C. A Review of Toxins from Cnidaria. *Mar Drugs*. 2020; 18(10), doi: 10.3390/md18100507, indexed in Pubmed: 33036158.
5. Tibballs J, Yanagihara AA, Turner HC, et al. Immunological and toxicological responses to jellyfish stings. *Inflamm Allergy Drug Targets*. 2011; 10(5): 438–446, doi: 10.2174/187152811797200650, indexed in Pubmed: 21824077.
6. Montgomery L, Seys J, Mees J. To Pee, or Not to Pee: A Review on Envenomation and Treatment in European Jellyfish Species. *Mar Drugs*. 2016; 14(7), doi: 10.3390/md14070127, indexed in Pubmed: 27399728.
7. Thompson TE, Bennett I. *Physalia* nematocysts: utilized by mollusks for defense. *Science*. 1969; 166(3912): 1532–1533, doi: 10.1126/science.166.3912.1532, indexed in Pubmed: 17742854.
8. Bourg N, Schaeffer A, Cetina-Heredia P, et al. Driving the blue fleet: Temporal variability and drivers behind bluebottle (*Physalia physalis*) beachings off Sydney, Australia. *PLoS One*. 2022; 17(3): e0265593, doi: 10.1371/journal.pone.0265593, indexed in Pubmed: 35299230.
9. Fenner PJ. Dangers in the ocean: the traveler and marine envenomation. I. jellyfish. *J Travel Med*. 1998; 5(3): 135–141, doi: 10.1111/j.1708-8305.1998.tb00487.x, indexed in Pubmed: 9772332.
10. Burnett JW, Hepper KP, Aurelian L, et al. Recurrent eruptions following unusual solitary coelenterate envenomations. *J Am*

- Acad Dermatol. 1987; 17(1): 86–92, doi: 10.1016/s0190-9622(87)70177-7, indexed in Pubmed: 2886519.
11. Burnett JW. Dysphonia: a new addition to jellyfish envenomation syndromes. Wilderness Environ Med. 2005; 16(2): 117–118, doi: 10.1580/1080-6032(2005)16[117:danatj]2.0.co;2, indexed in Pubmed: 15974264.
12. Chui JJ, Ooi KGJ, Reeves D, et al. Bluebottle envenomation-induced crystalline keratopathy. Cornea. 2011; 30(7): 835–837, doi: 10.1097/ICO.0b013e318203cfdb, indexed in Pubmed: 21389852.
13. Russell FE. *Physalia* stings: a report of two cases. Toxicon. 1966; 4(1): 65–67, doi: 10.1016/0041-0101(66)90068-7, indexed in Pubmed: 4381466.
14. Burnett J. TREATMENT OF VENOMOUS JELLYFISH STINGS. Natural Toxins. 1989: 160–164, doi: 10.1016/b978-0-08-036139-0.50019-1.
15. Stein MR, Marraccini JV, Rothschild NE, et al. Fatal Portuguese man-o'-war (*Physalia physalis*) envenomation. Ann Emerg Med. 1989; 18(3): 312–315, doi: 10.1016/s0196-0644(89)80421-4, indexed in Pubmed: 2564268.
16. Kajfasz P. A case of severe stinging caused by venomous marine animal, "Portuguese man of war" (*Physalia* species) in all probability. Int Marit Health. 2015; 66(2): 84–86, doi: 10.5603/IMH.2015.0020, indexed in Pubmed: 26119677.
17. Burnett JW. Lack of efficacy of a combination sunblock and "jellyfish sting inhibitor" topical preparation against *Physalia* sting. Dermatitis. 2005; 16(3): 151, doi: 10.1097/01206501-200509000-00016, indexed in Pubmed: 16408356.
18. Filling-Katz MR. Mononeuritis multiplex following jellyfish stings. Ann Neurol. 1984; 15(2): 213, doi: 10.1002/ana.410150223, indexed in Pubmed: 6142678.
19. Burnett JW, Gable WD. A fatal jellyfish envenomation by the Portuguese man-o-war. Toxicon. 1989; 27(7): 823–824, doi: 10.1016/0041-0101(89)90050-0, indexed in Pubmed: 2571201.
20. Spielman FJ, Bowe EA, Watson CB, et al. Acute renal failure as a result of *Physalia physalis* sting. South Med J. 1982; 75(11): 1425–1426, doi: 10.1097/00007611-198211000-00033, indexed in Pubmed: 6128793.
21. Auerbach PS, Hays JT. Erythema nodosum following a jellyfish sting. J Emerg Med. 1987; 5(6): 487–491, doi: 10.1016/0736-4679(87)90211-3, indexed in Pubmed: 2892880.
22. Manabe Y, Mabuchi T, Kawai M, et al. A Case of Delayed Flare-up Allergic Dermatitis Caused by Jellyfish Sting. Tokai J Exp Clin Med. 2014; 39(3): 90–94, indexed in Pubmed: 25248421.
23. Loredana Asztalos M, Rubin AI, Elenitsas R, et al. Recurrent dermatitis and dermal hypersensitivity following a jellyfish sting: a case report and review of literature. Pediatr Dermatol. 2014; 31(2): 217–219, doi: 10.1111/pde.12289, indexed in Pubmed: 24495001.
24. Giordano AR, Vito L, Sardella PJ. Complication of a Portuguese man-of-war envenomation to the foot: a case report. J Foot Ankle Surg. 2005; 44(4): 297–300, doi: 10.1053/j.jfas.2005.04.012, indexed in Pubmed: 16012438.
25. Singletary EM, Rochman AS, Bodmer JC, et al. Envenomations. Med Clin North Am. 2005; 89(6): 1195–1224, doi: 10.1016/j.mcna.2005.07.001, indexed in Pubmed: 16227060.
26. Cazorla-Perfetti DJ, Loyo J, Lugo L, et al. Epidemiology of the Cnidarian *Physalia physalis* stings attended at a health care center in beaches of Adicora, Venezuela. Travel Med Infect Dis. 2012; 10(5-6): 263–266, doi: 10.1016/j.tmaid.2012.09.007, indexed in Pubmed: 23067562.
27. Labadie M, Aldabe B, Ong N, et al. Portuguese man-of-war (*Physalia physalis*) envenomation on the Aquitaine Coast of France: an emerging health risk. Clin Toxicol (Phila). 2012; 50(7): 567–570, doi: 10.3109/15563650.2012.707657, indexed in Pubmed: 22780958.
28. Haddad V, Virga R, Bechara A, et al. An outbreak of Portuguese man-of-war (*Physalia physalis* - Linnaeus, 1758) envenoming in Southeastern Brazil. Rev Soc Bras Med Trop. 2013; 46(5): 641–644, doi: 10.1590/0037-8682-1518-2013, indexed in Pubmed: 23904083.
29. Maharani T, Widiastuti W. First envenomation report of the Cnidarian *Physalia physalis* in Indonesia. Int Marit Health. 2021; 72(2): 110–114, doi: 10.5603/IMH.2021.0019, indexed in Pubmed: 34212350.
30. Loten C, Stokes B, Worsley D, et al. A randomised controlled trial of hot water (45 degrees C) immersion versus ice packs for pain relief in bluebottle stings. Med J Aust. 2006; 184(7): 329–333, doi: 10.5694/j.1326-5377.2006.tb00265.x, indexed in Pubmed: 16584366.
31. Bowra J, Gillet M, Morgan J, et al. Randomised crossover trial comparing hot showers and ice packs in the treatment of *physalia* envenomation. Emerg Med. 2002; 14(A22).
32. Turner B, Sullivan P. Disarming the bluebottle: treatment of *Physalia* envenomation. Med J Aust. 1980; 2(7): 394–395, indexed in Pubmed: 6109229.
33. Exton DR. Treatment of *Physalia physalis* envenomation. Med J Aust. 1988; 149(1): 54, indexed in Pubmed: 2898725.
34. Burnett JW, Rubinstein H, Calton GJ. First aid for jellyfish envenomation. South Med J. 1983; 76(7): 870–872, doi: 10.1097/00007611-198307000-00013, indexed in Pubmed: 6135257.
35. Birsa LM, Verity PG, Lee RF. Evaluation of the effects of various chemicals on discharge of and pain caused by jellyfish nematocysts. Comp Biochem Physiol C Toxicol Pharmacol. 2010; 151(4): 426–430, doi: 10.1016/j.cbpc.2010.01.007, indexed in Pubmed: 20116454.
36. Wilcox CL, Headlam JL, Doyle TK, et al. Assessing the Efficacy of First-Aid Measures in *Physalia* sp. Envenomation, Using Solution- and Blood Agarose-Based Models. Toxins (Basel). 2017; 9(5), doi: 10.3390/toxins9050149, indexed in Pubmed: 28445412.
37. Choong C, Chan HZ, Faruk NA, et al. Jellyfish Envenomation Resulting In Vascular Insufficiency And Neurogenic Injury of Upper Limb. Malays Orthop J. 2015; 9(3): 49–51, doi: 10.5704/MOJ.1511.007, indexed in Pubmed: 28611910.
38. Junghans T, Bodio M. Medically important venomous animals: biology, prevention, first aid, and clinical management. Clin Infect Dis. 2006; 43(10): 1309–1317, doi: 10.1086/508279, indexed in Pubmed: 17051499.
39. Ballesteros A, Marambio M, Fuentes V, et al. Differing Effects of Vinegar on (Cnidaria: Scyphozoa) and (Cnidaria: Cubozoa) Stings-Implications for First Aid Protocols. Toxins (Basel). 2021; 13(8), doi: 10.3390/toxins13080509, indexed in Pubmed: 34437380.
40. Ballesteros A, Trullas C, Jourdan E, et al. Inhibition of Nematocyst Discharge from (Cnidaria: Scyphozoa)-Prevention Measures against Jellyfish Stings. Mar Drugs. 2022; 20(9), doi: 10.3390/md20090571, indexed in Pubmed: 36135760.
41. Ballesteros A, Marambio M, Trullas C, et al. Effect of Rinse Solutions on (Cnidaria: Scyphozoa) Stings and the Ineffective Role of Vinegar in Scyphozoan Jellyfish Species. Int J Environ Res Public Health. 2023; 20(3), doi: 10.3390/ijerph20032344, indexed in Pubmed: 36767709.
42. Cegolon L, Heymann WC, Lange JH, et al. Jellyfish stings and their management: a review. Mar Drugs. 2013; 11(2): 523–550, doi: 10.3390/md11020523, indexed in Pubmed: 23434796.

43. Gambini C, Abou B, Ponton A, et al. Micro- and macrorheology of jellyfish extracellular matrix. *Biophys J*. 2012; 102(1): 1–9, doi: 10.1016/j.bpj.2011.11.4004, indexed in Pubmed: 22225792.
44. Imamura K, Tsuruta D, Tsuchisaka A, et al. Anaphylaxis caused by ingestion of jellyfish. *Eur J Dermatol*. 2013; 23(3): 392–395, doi: 10.1684/ejd.2013.2030, indexed in Pubmed: 23797480.
45. Risk YJ, Cardoso JL, Haddad Junior V. Envenoming caused by a Portuguese man-o'-war (*Physalia physalis*) manifesting as purpuric papules. *An Bras Dermatol*. 2012; 87(4): 644–645, doi: 10.1590/s0365-05962012000400025, indexed in Pubmed: 22892787.
46. Kaufman MB. Portuguese man-of-war envenomation. *Pediatr Emerg Care*. 1992; 8(1): 27–28, doi: 10.1097/00006565-199202000-00007, indexed in Pubmed: 1351283.
47. Matusow RJ. Oral inflammatory response to a sting from a Portuguese man-of-war. *J Am Dent Assoc*. 1980; 100(1): 73–75, doi: 10.14219/jada.archive.1980.0022, indexed in Pubmed: 6101281.
48. Bennett G. Wanderings in new South Wales, Batavia, Pedir Coast, Singapore and China. Richard Bentley, London 1834: 9.
49. Cleland JB, Southcott RV. Injuries to Man from Marine Invertebrates in the Australian Region. Commonwealth of Australia, Canberra 1965: 31–32.